11.4.3. Pathology (III): Drug-Induced Lens Changes

- **Amiodarone**
  - antiarrhythmia medication
  - stellate pigment deposition in anterior cortical axis
    - very rarely visually significant
    - phenothiazines cause pigmented deposits in the anterior lens epithelium
  - pigment deposition in corneal epithelium
  - optic neuropathy
    - rare
- **Phenothiazines**
  - pigmented deposits in the anterior lens epithelium
    - axial configuration
      - 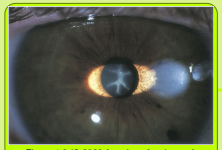
        Figure 4-9 (© 2020 American Academy of Ophthalmology)
  - generally visually insignificant
  - more likely to be seen with
    - chlorpromazine
    - thioridazine
      - dependent on
        - dose
        - treatment duration
      - **thioridazine (high-dose)**
        - severe retinopathy
          - confused with choroideremia or Bietti crystalline corneoretinal dystrophy
          - can develop within a few weeks-months
          - rare at doses <800 mg/day
          - coarse retinal pigment stippling in the posterior pole
            - blurred vision
          - widespread nummular patchy atrophy of pigment epithelium & choriocapillaris
            - visual field loss
            - night blindness
        - visual function can improve after drug stopped
          - sometimes deteriorates later if progressive chorioretinal atrophy
        - monitoring
          - no monitoring at standard doses
            - toxicity is rare
          - suspected cases
          - patients who have taken high doses
            - monitoring similar to chloroquine
- **Corticosteroids**
  - long-term use of corticosteroids may cause PSC
  - related to
    - dose
    - duration of treatment
  - several routes
    - topical
    - subconjunctival
    - intraocular
      - slow-release steroid repositories have not altered the IOP-elevating and PSC-producing effects of these medications
    - inhaled
    - systemic
  - patients susceptible to steroid-induced glaucoma are frequently those who develop PSC after intravitreal triamcinolone acetonide
  - histologically/clinically cannot be distinguished from senescent PSC
  - some steroid-induced PSCs in children may resolve with cessation of the drug
- **Tamoxifen**
  - the association previously suggested between cataract development and tamoxifen use has not been substantiated
- **Statins**
  - in studies on dogs, statins are associated with cataract when given in excessive doses
  - long-term use of statins in humans is not associated with an increased cataract risk
  - a longitudinal study reported a 50% reduction in the 5-year incidence of nuclear cataracts in patients treated with statins
  - concomitant use of simvastatin and erythromycin (which increases circulating statin levels) may be associated with 2x increased risk of cataract
- **Miotics (anticholinesterases)**
  - cataract formation
    - after 55 months of pilocarpine use
      - 20%
    - after echothiophate iodide use
      - 60%
  - first appears as small vacuoles within and posterior to the anterior lens capsule
    - appreciated on retroillumination
    - may progress to posterior cortical and nuclear changes
  - dependent on
    - dose frequency
    - treatment duration
    - age
      - visually significant cataracts are common in elderly patients
      - progressive cataract formation has not been reported in children

Ophthalmology Mind Maps/Arman Mashayekhi, MD