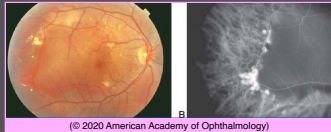
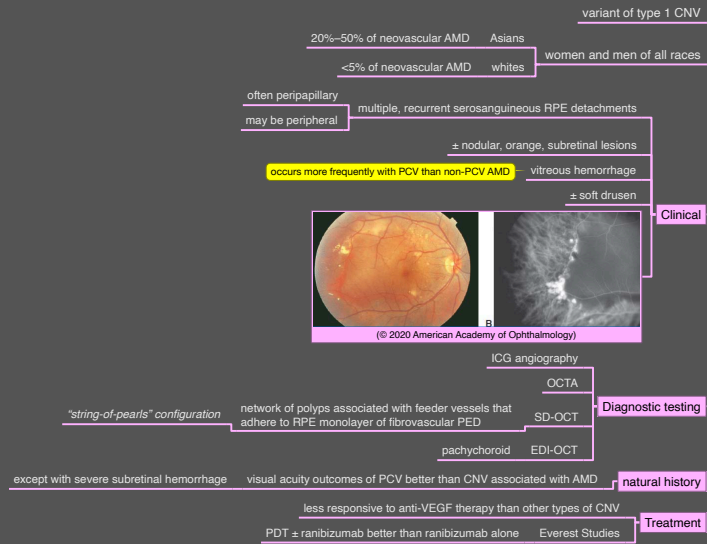
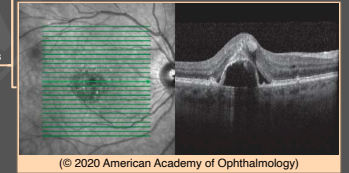
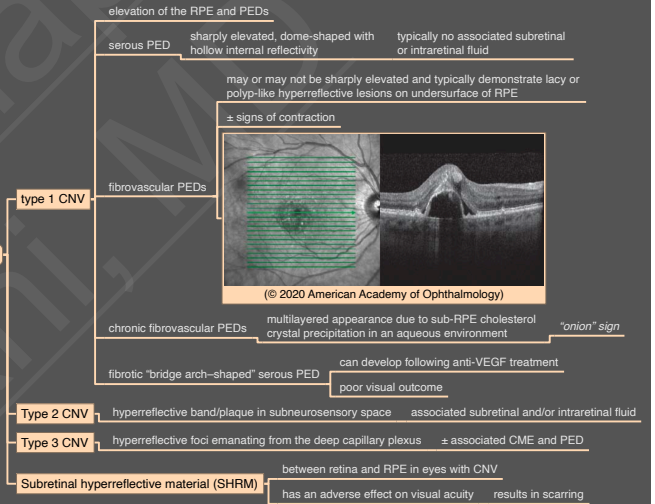


Neovascular AMD (II)



SD-OCT of CNV



OCT Angiography of CNV

