9.8.3. Endophthalmitis (III): Fungal Endophthalmitis (II)

- Fungi
  - Candida
    - yeast; pseudohyphate appearance
  - Aspergillus
    - septate hyphae; dichotomously branching
    - soil and decaying vegetation
  - Cryptococcus
    - yeast
    - contaminated soil and pigeon feces
    - India ink stain
  - Coccidioides immitis
    - dimorphic fungus
    - soil
    - Papanicolaou stain

Cryptococcosis

- Cryptococcus neoformans
  - yeast
  - found in contaminated soil and pigeon feces
    - Histoplasma capsulatum in bat droppings
  - inhalation of the aerosolized fungus
    - reaches the eye
      - hematogenously
        - begins as a focus in the choroid
          - subsequent extension and secondary involvement of overlying tissues
      - ± direct extension from the optic nerve
  - predilection for the central nervous system
    - the most common cause of fungal meningitis
      - ocular infections occur months after the onset of meningitis
  - causes severe disseminated disease among immunocompromised/debilitated patients
    - most frequent fungal eye infection in patients with HIV/AIDS
- ocular presentation
  - solitary or multiple discrete yellow-white chorioretinal lesions
    - varying markedly in size
    - postequatorial
  - granulomatous anterior cellular inflammation
  - variable degrees of vitritis
  - vascular sheathing
  - exudative retinal detachment
  - papilledema
- diagnostic workup
  - India ink stain
  - culture of the fungus from cerebrospinal fluid
- treatment
  - Intravenous amphotericin B
  - oral flucytosine
  - with optic nerve or macular involvement visual prognosis is poor

Coccidioidomycosis

- Coccidioides immitis
  - endemic to
    - dimorphic soil fungus
    - southwestern United States
    - southern California and the San Joaquin Valley
      - pulmonary infection
        - dissemination to the CNS, skin, skeleton, and eyes
          - <1% of patients with pulmonary coccidioidomycosis
    - parts of Central and South America
      - northern Mexico
      - Argentina
    - inhalation of dust-borne arthrospores
- systemic disease
  - 40% of infected patients are symptomatic
    - mild upper respiratory tract infection
      - 3 weeks after exposure
    - pneumonitis
    - erythema nodosum or multiforme
      - 3 days-3 weeks after the onset of symptoms
- ocular coccidioidomycosis
  - uncommon
    - even with disseminated disease
  - 1/2 of patients with ocular involvement have systemic disease
  - extraocular findings
    - blepharitis
    - keratoconjunctivitis
    - phlyctenular and granulomatous conjunctivitis
    - episcleritis and scleritis
    - extraocular nerve palsies
    - orbital infection
  - intraocular findings
    - <20 pathologically verified cases
    - unilateral or bilateral
    - anterior segment
      - granulomatous anterior uveitis
        - should be considered in the differential diagnosis of any patient with granulomatous iritis who has lived in or traveled through endemic areas
      - iris granulomas

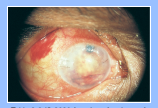

Table 8-6 (© 2020 American Academy of Ophthalmology)

    - posterior segment
      - multifocal chorioretinitis (choroidal granulomas)
        - similar to cryptococcosis
        - postequatorial fundus
        - may resolve –> punched-out chorioretinal scars
        - multiple, discrete, yellow-white lesions
          - <1 DD in size
      - serous retinal detachment
      - vitreous cellular infiltration
      - vascular sheathing
      - retinal hemorrhage
      - involvement of the optic nerve
- diagnostic workup
  - serologic testing
    - serum, cerebrospinal fluid, vitreous, and aqueous
    - complement-fixation titers often elevated (>1:32)
  - skin testing for exposure to coccidioidin
  - anterior chamber tap
    - for isolated anterior segment involvement
    - Papanicolaou stain
    - culturing for the organism may delay diagnosis
- pathology
  - pyogenic, granulomatous, and mixed reactions
  - zonal granulomatous inflammation
  - Coccidioides organisms are usually visible
- differential diagnosis
  - Candida
  - Aspergillus
  - Histoplasma
  - tuberculous uveitis
- treatment
  - infectious diseases specialist
  - oral azole antifungal drug
    - fluconazole
    - itraconazole
  - amphotericin B
    - reserved for lesions worsening rapidly or located in vital sites (e.g. spine)
    - surgical debulking of anterior chamber granulomas
  - pars plana vitrectomy
    - intraocular injections of amphotericin and voriconazole
  - poor visual prognosis
    - most eyes require enucleation because of pain and blindness
    - with systemic disease, higher doses and longer duration is needed

Ophthalmology Mind Maps/Arman Mashayekhi, MD