4.6.2. Cornea (II): Inflammations

Acanthamoeba keratitis

- contaminated stagnant water
  - hot tubs
  - ponds
- soft contact lens wear
- organisms
  - Acanthamoeba castellani
  - Acanthamoeba polyphagia
- clinical features
  - severe pain
  - radial keratoneuritis
  - ring infiltrate
- diagnosis
  - culture
    - late stage disease
      - organism penetrates into deep stroma
        - difficult to isolate from superficial scraping
    - nonnutrient blood agar layered with E. coli
  - confocal microscopy
  - histology
    - cysts
    - trophozoites
    - stain
      - PAS
      - H&E
      - calcofluor white
      - acridine orange

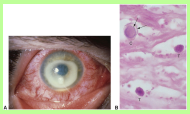

Figure 6-8 (© 2020 American Academy of Ophthalmology)

Infectious crystalline keratopathy

- predisposing factor
  - long-term topical corticosteroid use
- organisms
  - alpha-hemolytic streptococcus viridans
  - other bacteria
  - fungi
- clinical features
  - crystalloid appearance of the opacity
    - no true crystals
    - along suture track
  - intact overlying epithelium
    - difficult to culture!
- histology
  - bacterial colonies in stroma
    - Gram stain
    - GMS stain
    - PAS stain
    - H&E
  - little inflammatory cell infiltrate

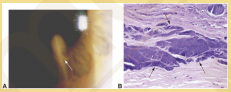

Figure 6-9 (© 2020 American Academy of Ophthalmology)

Interstitial keratitis

- chronic/recurrent IK
  - stromal scarring
- intact overlying epithelium
- vascularization
- inflammatory cell infiltration in stroma
- nonsuppurative
- immunologic response to microorganisms
- organisms
  - congenital syphilis
    - transplacental infection by Treponema pallidum
  - herpes simplex
    - most common cause
  - Mycobacterium tuberculosis/Mycobacterium leprae
  - Borrelia burgdoferi
  - E-B virus

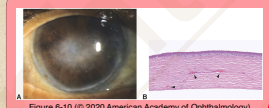

Figure 6-10 (© 2020 American Academy of Ophthalmology)

Non-infectious keratitis

- autoimmune disease
  - rheumatoid arthritis
  - graft-vs-host disease
- topical medication toxicity
  - anesthetics
  - NSAIDs
  - antivirals

Bacterial infections

- results from disruption of corneal epithelium
- common bacteria
  - pseudomonas aeruginosa
  - staphylococcus aureus
  - streptococcus pneumoniae
  - enterobacteriacae
- corneal scraping
  - neutrophils
  - necrotic debris
  - bacteria on Gram stain

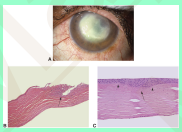

Figure 6-5 (© 2020 American Academy of Ophthalmology)

Herpes simplex virus keratitis

- dendrite
  - linear arborizing pattern
    - shallow ulceration
    - epithelial cell swelling
  - histology
    - subepithelial infiltration by chronic inflammatory cells
    - loss of the Bowman layer
- stromal keratitis
  - may accompany or follow epithelial infection
  - stromal scarring ± vascularization
  - interstitial keratitis
    - chronic inflammatory cells
    - vascularization
- endotheliitis
  - granulomatous reaction at the level of Descemet's membrane
  - disciform keratitis
- diagnosis
  - corneal scraping
    - Giemsa stain
      - intranuclear viral inclusions
  - viral culture
  - antigen detection
  - PCR
- postherpetic neurotrophic keratopathy
  - corneal anesthesia
  - featureless corneal stroma with paucity of keratocytes

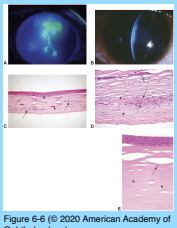

Figure 6-6 (© 2020 American Academy of Ophthalmology)

Fungal keratitis

- etiology
  - trauma
    - vegetable/plant
  - contact lens wear
  - topic corticosteroid use
- organisms
  - septated filamentous
    - aspergillus
    - fusarium
  - nonseptated filamentous
    - mucor
  - yeast
    - candida
- diagnosis
  - culture
    - sabouraud agar
  - corneal biopsy
    - histologic evaluation
      - Grocott-Gomori methenamine-silver nitrate (GMS)
      - PAS
    - PCR



Figure 6-7 (© 2020 American Academy of Ophthalmology)

- fungi can extend into anterior chamber
  - unlike bacteria!

Ophthalmology Mind Maps/Arman Mashayekhi, MD