9.6.18. Panuveitis (II): Sympathetic Ophthalmia

epidemiology
- earlier estimates of the incidence of SO
  - ≤0.5% in eyes with nonsurgical trauma and 10/100,000 after intraocular surgery
- most recent minimum incidence estimate is low (0.03/100,000)
- M=F
- lower risk in children
- increased risk in older patients

pathogenesis
- until recently, penetrating ocular injury was the most common precipitating event
- ocular surgery—particularly vitreoretinal surgery—is now the main precipitating event
  - in the early 1980s
    - 0.01% after pars plana vitrectomy
    - 0.06% after vitrectomy in the context of penetrating ocular injury
  - recent studies
    - risk of developing SO following pars plana vitrectomy is >2x this figure
- surgery or penetrating ocular injury complicated by incarceration of uveal tissue
  - exposure of uveoretinal antigens to conjunctival lymphatic channels
    - altered T-lymphocyte response to previously sequestered ocular self-antigens (derived from the RPE or choroid)
- genetic predisposition
  - HLA-DR4, -DRw53, and -DQw3
  - immunogenetics of SO and VKH syndrome are virtually identical
- latent period after surgery/injury
  - 80% within 3 months of injury
  - 90% within 1 year
  - in a recent series
    - only 1/3 within 3 months
    - <1/2 within 1 year
- enucleation within 2 weeks of injury to prevent SO should be considered in patients with grossly disorganized globes with no discernible visual function
- enucleation preferred to evisceration for the removal of ocular contents in severely injured eyes

clinical presentation
- asymmetric bilateral
  - exciting eye
  - latent period
  - sympathizing eye
- symptoms
  - minimal problems in near vision, mild photophobia, and slight redness to severe granulomatous anterior uveitis
- diffuse, granulomatous, nonnecrotizing panuveitis
  - exciting eye exhibits more severe inflammation than the sympathizing eye, at least initially
- anterior segment findings
  - mutton-fat KPs
  - thickening of the iris
  - posterior synechiae

Figure 6-58 (© 2020 American Academy of Ophthalmology)

  - elevated IOP due to trabeculitis
  - hypotony as a result of ciliary body shutdown
- posterior segment findings
  - moderate to severe vitritis
  - yellowish white, midequatorial choroidal lesions (Dalen-Fuchs nodules)
    - may become confluent

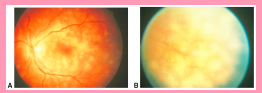

Figure 6-59 (© 2020 American Academy of Ophthalmology)

  - peripapillary choroidal lesions
  - exudative retinal detachment
- complications
  - cataract
  - chronic CME
  - peripapillary and macular CNV
  - optic atrophy
  - new complications in the sympathizing eye develop at a rate of 40% per person-year
- risk factors for poor vision in the sympathizing eye
  - traumatic etiology
  - active intraocular inflammation
  - exudative retinal detachment
- extraocular findings similar to VKH syndrome
  - cerebral spinal fluid pleocytosis
  - sensory neural hearing disturbance
  - alopecia
  - poliosis
  - vitiligo
  - uncommon

diagnostic tests
- FA
  - acute stage
    - multiple hyperfluorescent sites of leakage at the level of the RPE during the venous phase
  - pooling of dye beneath areas of exudative retinal detachment
  - Dalen-Fuchs lesions may appear hypofluorescent early in the study or hyperfluorescent with late staining

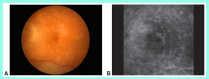

Figure 6-60 (© 2020 American Academy of Ophthalmology)

- ICG angiography
  - numerous hypofluorescent foci
    - intermediate phase of the angiogram
    - may become isofluorescent in the late stage

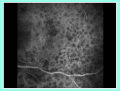

Figure 6-61 (© 2020 American Academy of Ophthalmology)

- OCT imaging
  - shallow, serous retinal detachment
  - intraretinal edema
- B-scan ultrasonography
  - choroidal thickening

pathology
- similar for both the exciting and sympathizing eyes
- diffuse, granulomatous, nonnecrotizing inflammation
  - spares the choriocapillaris in the early stage
- Dalen-Fuchs nodules
  - clusters of epithelioid cells located between RPE and Bruch membrane
  - 1/3
  - also in VKH syndrome and sarcoidosis
  - not specific to SO

differential diagnosis
- TB, sarcoidosis, syphilis, fungal infections, traumatic or postoperative endophthalmitis
- lens-associated uveitis
  - reported with SO in ≤25% of cases
- VKH syndrome
  - clinical presentations of SO and VKH syndrome may be strikingly similar
  - history of prior ocular injury is by definition absent in patients with VKH syndrome
    - clinical course

management
- once SO has become established, enucleation of the exciting eye will not alter the disease course
- exciting eye may eventually become the better-seeing eye!
- treatment of the acute anterior uveitis
  - systemic corticosteroids
  - IMT
    - corticosteroid-sparing drugs
  - topical corticosteroids
  - cycloplegic and mydriatic agents
  - periocular corticosteroids
    - to manage inflammatory recurrences and CME
  - intravitreal corticosteroids
    - patients intolerant of systemic corticosteroid therapy
  - intravitreal fluocinolone acetonide implant

clinical course & prognosis
- chronic with frequent exacerbations
- untreated leads to loss of vision and phthisis bulbi
- with prompt and aggressive systemic therapy, the visual prognosis is good in the sympathizing eye
  - 60% of patients achieve a final visual acuity of 20/40
  - up to 25% may decline to ≤20/200

Ophthalmology Mind Maps/Arman Mashayekhi, MD