4.8.1. Sclera

Congenital anomalies

- Choristoma
  - Epibulbar dermoid
  - Episcleral osseous choristoma
- Nanophthalmos
  - bilateral
  - short axial length = 15-20 mm
  - normal or slightly enlarged lens
  - thick sclera
  - caused by
    - predisposition to uveal effusion
    - reduced protein permeability
    - impaired venous outflow
- glaucoma
  - angle closure
  - pupillary block
  - elevated episcleral venous pressure
- histology
  - fraying/splitting of collagen fibrils
  - abnormal glycosaminoglycan matrix

Degenerations

- Senile Calcific Plaque
  - elderly
  - clinical findings
    - flat
    - firm
    - sharply circumscribed
    - gray
    - rectangular/ovoid
    - <=1cm
    - bilateral
    - anterior to medial & lateral rectus muscle insertions
  - histology
    - calcium
      - midportion of scleral stroma
      - granular deposition - confluent plaque
      - stains
        - von Kossa
        - alizarin red

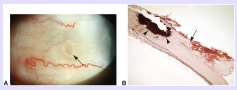
Figure 8-8 (© 2020 American Academy of Ophthalmology)

- Scleral staphyloma
  - scleral ectasia lined by uveal tissue
  - predisposing conditions
    - scleritis

Figure 8-7 (© 2020 American Academy of Ophthalmology)

    - thin sclera posterior to rectus muscle insertions
    - long-standing increased intraocular pressure in children
    - axial myopia in children

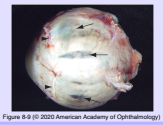
Figure 8-9 (© 2020 American Academy of Ophthalmology)

  - histology
    - thin sclera
    - +- fibrosis/scarring

Neoplasia

- Fibrous histiocytoma
  - also know as
    - fibroxanthoma
    - fibrohistiocytic tumor
  - clinical findings
    - corneoscleral limbus
    - gelatinous gray vascularized nodule
    - more common in the orbit
  - histology
    - proliferation of fibrocytes & histiocytes
    - whorled pattern

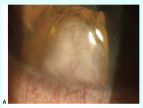
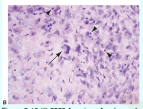
Figure 8-10 (© 2020 American Academy of Ophthalmology)

- malignant fibrous histiocytoma
  - increased mitotic activity
  - nuclear pleomorphism
  - necrosis
  - invasive growth pattern
  - does not metastasize
- Nodular fasciitis
  - young adults
  - clinical findings
    - rapidly growing
    - round-oval
    - firm
    - white-gray nodule
    - 0.5-1.5 cm
    - location
      - limbus
      - anterior to rectus muscle insertion
  - histology
    - spindle cell proliferation
      - resemble firbroblasts growing in tissue culture
      - aggregate in short fascicles
      - no unbalanced mitosis
      - +- mitotic figures
        - may be misdiagnosed as sarcoma!
    - vascular myxoid stroma
      - chronic inflammatory infiltrate
      - foci of dense collagen deposition

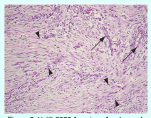
Figure 8-11 (© 2020 American Academy of Ophthalmology)

Topography

- temporal sclera from mesoderm
- neural crest derivative
- covers 4/5 to 5/6 of eye surface area
- posteriorly
  - outer 2/3 merges with dura of optic nerve
  - inner 1/3 continues as lamina cribrosa
- dimensions
  - diameter = 22 mm
  - thickness
    - posteriorly = 1 mm
    - posterior to muscle insertions = 0.3 mm

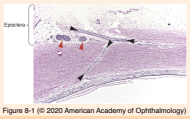

Figure 8-1 (© 2020 American Academy of Ophthalmology)

- layers
  - episclera
    - loose fibrovascular tissue
  - stroma
    - type I collagen
      - 28-300 nm
      - compared to corneal collagen fibers, scleral fibers are:
        - thicker
        - more variable in thickness
        - more variable in orientation
    - emissary channels
      - posteriorly
        - posterior ciliary arteries
        - posterior ciliary nerves
      - equatorial
        - vortex veins
      - anteriorly
        - anterior ciliary arteries/veins
        - long posterior ciliary nerves (Axenfeld nerve loops)

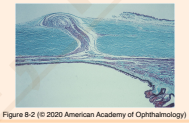
Figure 8-2 (© 2020 American Academy of Ophthalmology)

  - lamina fusca
    - pigmented, fibrovascular tissue
    - binds uvea to sclera
    - strongest uveoscleral attachments
      - major emissary channels
      - anterior base of ciliary body
      - juxtapapillary region

Inflammations

- Episcleritis
  - Simple episcleritis
    - 3rd-5th decade
    - female=male
    - clinical
      - slightly tender sectorial red area
      - anterior episclera
    - predisposing condition
      - none
    - histology
      - vascular congestion
      - stromal edema
      - chronic nongranulomatous perivascular inflammation

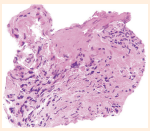
Figure 8-3 (© 2020 American Academy of Ophthalmology)

  - Nodular episcleritis
    - female=male
      - in contrast to simple episcleritis
    - clinical
      - tender pink-red nodule
      - anterior episclera
    - predisposing condition
      - systemic disease
        - rheumatoid arthritis
      - in contrast to simple episcleritis
    - histology
      - necrobiotic granulomatous inflammatory infiltrate
        - palisading epithelioid histiocytes
        - central core of necrotic collagen
          - in contrast to simple episcleritis
- Scleritis
  - clinical
    - painful
    - progressive
  - predisposing condition
    - systemic autoimmune connective tissue diseases
  - Necrotizing scleritis
    - types
      - nodular

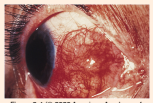
Figure 8-4 (© 2020 American Academy of Ophthalmology)

      - diffuse
        - brawny scleritis

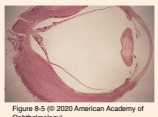
Figure 8-5 (© 2020 American Academy of Ophthalmology)

    - histology
      - necrobiotic granuloma
        - central necrotic collagen
          - severe scleral thinning/ectasia
            - herniation of uveal tissue
              - scleromalacia perforans
        - palisading epithelioid histiocytes/ multinucleated giant cells
        - peripheral rim of lymphocytes/plasma cells

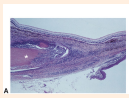
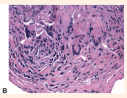
Figure 8-6 (© 2020 American Academy of Ophthalmology)

  - Nonnecrotizing scleritis
    - nongranulomatous perivascular lymphocytic/ plasmacytic infiltrate
    - +- vasculitis
      - fibrinoid necrosis of vessel wall

Ophthalmology Mind Maps
Arman Mashayekhi, MD