11.3.5. Developmental Defects (IV): Congenital Cataract (II)

Membranous

- lens proteins are resorbed from either an intact or a traumatized lens
  - the anterior and posterior lens capsules fuse into a dense white membrane
- significant visual disability

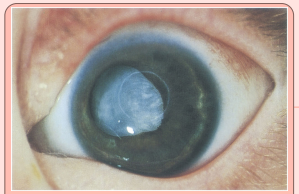

Figure 3-14 (© 2020 American Academy of Ophthalmology)

Complete (total)

- all of the lens fibers are opacified
  - may be subtotal at birth and progress rapidly
- unilateral or bilateral
- red reflex is completely obscured
- profound visual impairment

Congenital rubella syndrome

- maternal infection with the rubella virus (RNA togavirus)
  - especially if the infection occurs during the first trimester
- systemic manifestations
  - cardiac defects
  - deafness
  - mental disability
- ocular manifestations
  - cataract
    - pearly white nuclear opacifications
    - the cortex may liquefy
      - +- complete cataract
    - lens-fiber nuclei are retained deep within the lens substance
    - live virus particles may be recovered from the lens as late as 3 years after birth
    - cataract removal may be complicated by excessive postoperative inflammation
      - release of live virus particles!
  - diffuse pigmentary retinopathy
  - microphthalmos
  - glaucoma
    - cataract and glaucoma are not present simultaneously!
  - transient or permanent corneal clouding

Coronary

- club-shaped cortical opacities arranged around the equator of the lens like a crown, or corona
- autosomal dominant
- cannot be seen unless the pupil is dilated
- do not affect visual acuity

Cerulean

- small bluish opacities located in the lens cortex
  - blue-dot cataracts
- nonprogressive
- do not cause visual symptoms

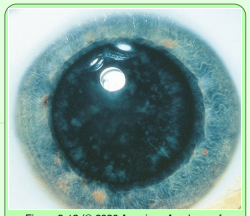

Figure 3-12 (© 2020 American Academy of Ophthalmology)

Nuclear

- opacities of the embryonic nucleus alone or of both embryonic and fetal nuclei
- complete nucleus or discrete layers within the nucleus
- bilateral
- +- microphthalmia
- risk of developing aphakic glaucoma

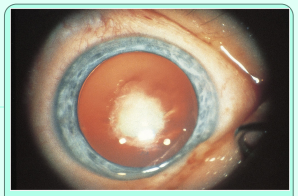

Figure 3-13 (© 2020 American Academy of Ophthalmology)

Capsular

- small opacifications of the lens epithelium and anterior lens capsule
  - spare the cortex
  - differentiated from anterior polar cataracts by their protrusion into the anterior chamber
- generally do not adversely affect vision

Ophthalmology Mind Maps/Arman Mashayekhi, MD