8.3.10. Systemic Conditions Associated With Ocular Surface Disorders (II)

Vitamin A Deficiency

- **epidemiology**
  - 20,000–100,000 new cases of blindness worldwide/year
  - malnourished infants and babies born to vitamin A–deficient mothers
    - especially infants who have another biological stressor, such as measles or diarrhea
  - superficial concurrent infections further predispose to keratomalacia and blindness
    - herpes simplex
    - measles
    - bacterial agents
- **pathogenesis**
  - low dietary intake of vitamin A
    - malnutrition
    - unusual self-imposed dietary practices
    - chronic alcoholism
  - decreased absorption of vitamin A
    - lipid malabsorption
      - cystic fibrosis
      - biliary cirrhosis
      - bowel resection
        - gastric bypass surgery
- **clinical presentation**
  - loss of mucus production by goblet cells
    - dryness of the conjunctiva and cornea (xerosis)
      - Bitôt spot
        - superficial foamy, gray triangular area on bulbar conjunctiva in palpebral aperture
        - histopathology
          - keratinized epithelium
          - inflammatory cells
          - debris
            - Corynebacterium xerosis bacilli
              - metabolize the debris, producing the foamy appearance

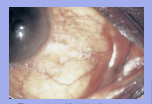

Figure 3-27 (© 2020 American Academy of Ophthalmology)

  - corneal ulcers and scars
    - diffuse corneal necrosis (keratomalacia)
  - 3 stages
    - conjunctival xerosis, without (X1A) or with (X1B) Bitôt spots
    - corneal xerosis (X2)
    - corneal ulceration, with keratomalacia involving <1/3 (X3A) or >1/3 (X3B) of the corneal surface
  - similar changes in gastrointestinal, genitourinary, and respiratory tracts
- **management**
  - medical emergency
    - untreated mortality rate of 50%
  - oral or parenteral vitamin A
    - malabsorption may prevent oral administration from being effective in patients with acute vitamin A deficiency
  - protein-calorie supplementation
  - identification and proper treatment of underlying causes
  - ocular
    - corneal lubrication
    - prevention of secondary infection and corneal melting

Xeroderma Pigmentosum

- rare
- recessively transmitted
- impaired ability to repair sunlight-induced damage to DNA
- skin findings
  - exposed skin develops focal hyperpigmentation, atrophy, actinic keratosis, and telangiectasia
    - first or second decade of life
  - cutaneous neoplasms
    - squamous cell carcinoma
    - basal cell carcinoma
    - melanoma
- ophthalmic manifestations
  - signs and symptoms of KCS
    - photophobia
    - tearing
    - blepharospasm
  - conjunctiva
    - dryness
    - inflammation
    - telangiectasia
    - hyperpigmentation
    - pingueculae and pterygia
  - cornea
    - exposure keratitis
    - ulceration
    - neovascularization
    - scarring
    - perforation
    - keratoconus
    - band-shaped nodular corneal dystrophy
    - gelatinous dystrophy
  - eyelids
    - atrophy
      - even loss of the entire lower eyelid
    - madarosis
    - trichiasis
    - scarring
    - symblepharon
    - entropion
    - ectropion
  - ocular neoplasms
    - 11%
    - most frequently at the limbus
    - squamous cell carcinoma
      - most common
    - basal cell carcinoma
    - melanoma

Ophthalmology Mind Maps/Arman Mashayekhi, MD