4.5.2. Conjunctiva (II): Conjunctivitis

Non-Infectious Conjunctivitis

- Types
  - Most cases of papillary conjunctivitis
  - Some granulomatous conjunctivitis
  - Toxic follicular conjunctivitis
- Ocular cicatricial pemphigoid
  - Autoimmune
  - Other mucous membranes
  - ± Skin involvement
- Conjunctival biopsy
  - Routine histology — Submit half in formalin
    - Epithelial bullae
    - Subepithelial band of chronic inflammatory cells (plasma cells)
  - Immunofluorescence analysis — Submit half in Michel medium or saline
    - Immunoglobulins
      - IgG
      - IgM
      - IgA
    - Complement
      - C3
    - Sensitivity = 50%
    - Negative result does not rule out OCP!
    - Epithelial basement membrane

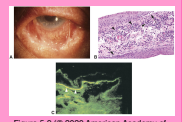

Figure 5-9 (© 2020 American Academy of Ophthalmology)

Infectious Conjunctivitis

- Most common pathogens
  - Children
    - H. influenzae
    - S. pneumoniae
  - Adults
    - Viral
      - Adenovirus
        - Corneal subepithelial infiltrates
      - Herpes viruses
        - Corneal ulcer
- Pathogens
  - Chlamydiae
    - Obligate intracellular pathogens
    - Follicular conjunctivitis
    - C. trachomatis
      - Serotypes A, B, C
        - Trachoma
      - Serotypes D-K
        - Adult & neonatal inclusion conjunctivitis
    - Diagnosis
      - Exfoliative cytology
      - Tissue biopsy
      - Intracellular organisms
  - Fungi
    - Typically involve the cornea
  - Microsporidia
    - Obligate intracellular parasites
    - Keratoconjunctivitis
    - AIDS
  - Rhinosporidium seeberi
    - Protozoon
    - India, Southeast Asia
    - Exposure to stagnant water
    - Isolated conjunctivitis
    - Palpebral/forniceal conjunctivitis
  - Acanthamoeba
    - Protozoon
    - Keratoconjunctivitis
    - Isolated chronic unilateral conjunctivitis
    - Exfoliative cytology

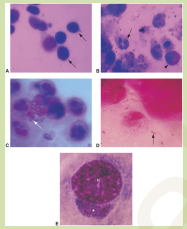

Figure 5-8 (© 2020 American Academy of Ophthalmology)

Inflammations

- Papillary Conjunctivitis
  - Closely packed flat-topped projections
    - Red on surface, pale at base
    - Upper tarsal conjunctiva — Giant papillary conjunctivitis
    - Histology
      - Epitheilum
      - Central vascular core
      - Stroma
        - Eosinophils
        - Lymphocytes
        - Plasma cells
        - Mast cells

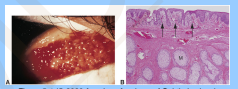

Figure 5-4 (© 2020 American Academy of Ophthalmology)

  - Etiology
    - Allergic immune response
      - Vernal conjunctivitis — Limbal papillae — Horner-Trantas dots
      - Atopic keratoconjunctivitis
    - Foreign body
      - Contact lens
      - Prosthesis
- Follicular conjunctivitis
  - Small dome-shaped nodules
    - Pale on surface, red at base
    - Lower forniceal and palpebral conjunctiva
    - Histology — Lymphoid follicle
      - Germinal center — Immature proliferating lymphocytes
      - Corona — Mature lymphocytes and plasma cells

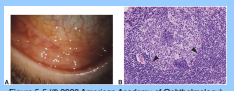

Figure 5-5 (© 2020 American Academy of Ophthalmology)

  - Etiology
    - Viruses
    - Atypical bacteria
    - Toxins
      - Brimonidine
      - Ophthalmic decongestants
- Granulomatous conjunctivitis — Etiology
  - Infectious
    - Parinaud oculoglandular syndrome — Granulomatous conjunctivitis + preauricular lymphadenopathy
    - Bacteria
      - Bartonella henselae (cat-scratch disease)
      - Francisella tularensis (tularemia)
      - Mycobacteria (tuberculosis)
      - Treponemes (syphylis)
    - Diagnosis
      - Serology
      - Culture
      - PCR
    - Histology
      - Central necrosis
        - "Caseation"
        - Infectious granulomatous conjunctivitis
      - Bacteria
  - Non-infectious
    - Sarcoidosis
      - Clinical
        - Small tan nodules — Forniceal conjunctiva
        - Non-injected asymptomatic eye
      - Histology — Noncaseating granulomatous tubercles
        - No central necrosis
        - Aggregates of epithelioid histiocytes
        - +- Multinucleated giant cells
        - Cuff of lymphocytes and plasma cells

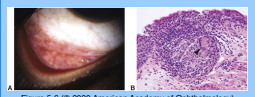

Figure 5-6 (© 2020 American Academy of Ophthalmology)

    - Foreign body granuloma
      - Multinucleated giant cells
      - Polarized light

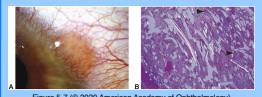

Figure 5-7 (© 2020 American Academy of Ophthalmology)

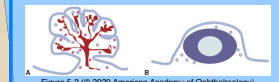

Figure 5-3 (© 2020 American Academy of Ophthalmology)

Ophthalmology Mind Maps/Arman Mashayekhi, MD