9.7.4. Infectious Ocular Inflammatory Diseases (IV): Cytomegalovirus (CMV)

Introduction

- Herpesviridae family
  - double-stranded DNA virus
- most common cause of congenital viral infection
- CMV retinitis
  - the most common ophthalmic manifestation of both congenital CMV infection and of CMV as an opportunistic infection
- causes illness in immunocompromised patients
  - leukemia
  - lymphoma
  - HIV/AIDS
    - before introduction of combination antiretroviral therapy
      - 30% of patients with HIV/AIDS developed CMV retinitis
        - rhegmatogenous retinal detachments with multiple breaks developed in 33% per eye per year
    - combination antiretroviral regimens
      - 80% decline in new cases/year of CMV retinitis
      - new cases of CMV retinitis continue to occur among patients who
        - fail combination antiretroviral treatment
        - abandon treatment
        - experience immune reconstitution but do not develop CMV-specific immunity
    - CMV retinitis confers a twofold increased risk in mortality among patients with a CD4+ T-cell count <100 cells/μL
    - resistant CMV infection in patients with CMV retinitis is further associated with increased mortality
  - transplant recipients
  - systemic immunomodulation

Pathogenesis

- virus reaches the eye hematogenously
  - infects retinal vascular endothelial cells
    - crosses the blood–ocular barrier
      - cell-to-cell transmission within the retina

clinical presentation

- 3 distinct variants
- classic or fulminant retinitis
  - early retinitis
    - small, white retinal infiltrate masquerading as a cotton-wool spot
      - inevitable progression without treatment
  - large areas of retinal hemorrhage against a background of whitened, edematous, or necrotic retina

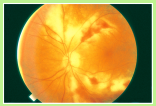

Figure 7-7 (© 2020 American Academy of Ophthalmology)

  - posterior pole, from the disc to the vascular arcades, in the distribution of the nerve fiber layer
  - associated with blood vessels
- granular or indolent form
  - retinal periphery
  - little or no retinal edema, hemorrhage, or vascular sheathing

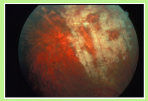

Figure 7-8 (© 2020 American Academy of Ophthalmology)

  - active retinitis progressing from the borders of the lesion
- perivascular form
  - variant of "frosted-branch" angiitis, an idiopathic retinal perivasculitis initially described in immunocompetent children

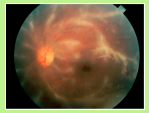

Figure 7-9 (© 2020 American Academy of Ophthalmology)

Diagnostic tests

- diagnosis of CMV retinitis in patients with HIV/AIDS or undergoing IMT is essentially clinical
- immunocompromised patients with atypical lesions or whose disease is not responding to anti-CMV therapy
  - PCR (aqueous or vitreous)
    - high sensitivity and specificity
    - to differentiate CMV from other herpetic causes of necrotizing retinitis and from toxoplasmic retinochoroiditis

Pathology

- full-thickness, coagulative necrotizing retinitis

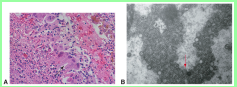

Figure 7-10 (© 2020 American Academy of Ophthalmology)

- secondary diffuse choroiditis
- infected retinal cells show pathognomonic cytomegalic changes
  - large eosinophilic intranuclear inclusions
  - small, multiple, basophilic cytoplasmic inclusions
  - viral inclusions may be present in RPE and vascular endothelium
- electron microscopy
  - viral particles with the typical morphology of the herpes family

CMV anterior uveitis

- in contrast to CMV retinitis
  - immunocompetent adults
- associated with
  - chronic or recurrent unilateral anterior uveitis
  - ocular hypertension
  - corneal edema
  - variable degrees of sectoral iris atrophy
    - similar to VZV
- diagnosis
  - demonstration of CMV DNA by PCR analysis
  - intraocular antibodies directed against CMV by enzyme-linked immunosorbent assay (ELISA)
  - negative study results for HSV and VZV
- treatment
  - valganciclovir
    - specific, prolonged, systemic anti-CMV treatment
  - relapses are common after discontinuation of therapy

Congenital CMV retinitis

- associated with other systemic manifestations of disseminated disease
  - fever
  - thrombocytopenia
  - anemia
  - pneumonitis
  - hepatosplenomegaly
- prevalence
  - 11%-22%
- diagnosis of congenital disease
  - associated systemic disease findings
  - clinical fundus appearance
  - evidence of viral inclusion bodies or positive PCR in urine, saliva, and subretinal fluid
- complement-fixation test
  - of value 5–24 months after the loss of the maternal antibodies
- resolution of the retinitis leaves both pigmented and atrophic lesions
- CMV retinitis can occur later in life
  - children with congenital CMV infection should be monitored at regular intervals for potential ocular involvement later into childhood
- complications
  - retinal detachment
    - ≤1/3
  - optic atrophy
  - cataract

Management

- antiretroviral therapy
  - Intravenous acyclovir for HSV & VZV
- anti-CMV therapy
  - high-dose intravenous induction
    - ganciclovir (5 mg/kg twice daily)
    - foscarnet (90 mg/kg twice daily)
      - effective against CMV and also HSV-1 & HSV-2
    - x2 weeks
  - low-dose oral maintenance therapy
    - antiretroviral therapy–naive patients
      - may require only 6 months of anti-CMV therapy
    - antiretroviral therapy–experienced patients
      - may require long-term maintenance therapy
    - patients on antiretroviral therapy with sustained immune recovery
      - (CD4+ T lymphocytes ≥100 cells/μL x 3–6 months)
      - systemic anti-CMV maintenance therapy may be safely discontinued
        - remain at risk for recurrence
          - monitor at 3-month intervals
  - oral valganciclovir (900 mg twice daily)
    - x3 weeks
    - followed by maintenance therapy (900 mg/day)
    - effective against CMV
  - intravitreal injection of ganciclovir or foscarnet
    - highly effective in treating intraocular disease
    - particularly effective for patients with vision-threatening posteriorly located retinitis
    - useful alternative in patients who cannot tolerate intravenous systemic therapy (myelotoxicity)
    - leaves extraocular systemic CMV and the fellow eye untreated
      - intravitreal injection + oral valganciclovir may obviate this limitation
  - aggressive anti-CMV therapy initiated at the same time as antiretroviral treatment may decrease the incidence of immune recovery uveitis

Ophthalmology Mind Maps/Arman Mashayekhi, MD