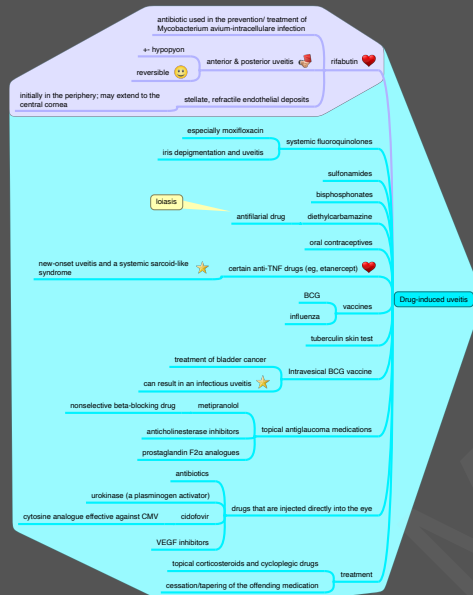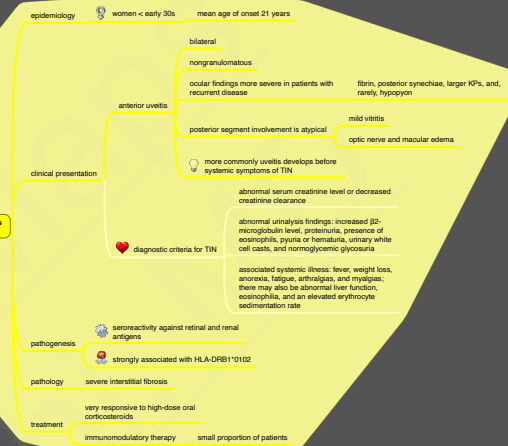
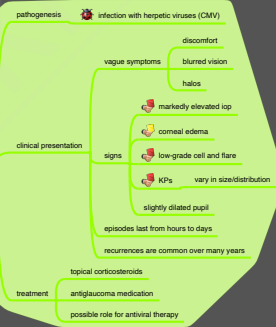


### Tubulointerstitial nephritis and uveitis syndrome (TINU)



### Glaucosarcoidosis (Posner-Schlossman syndrome)



## 9.6.3. Anterior Uveitis (III)

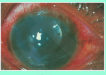
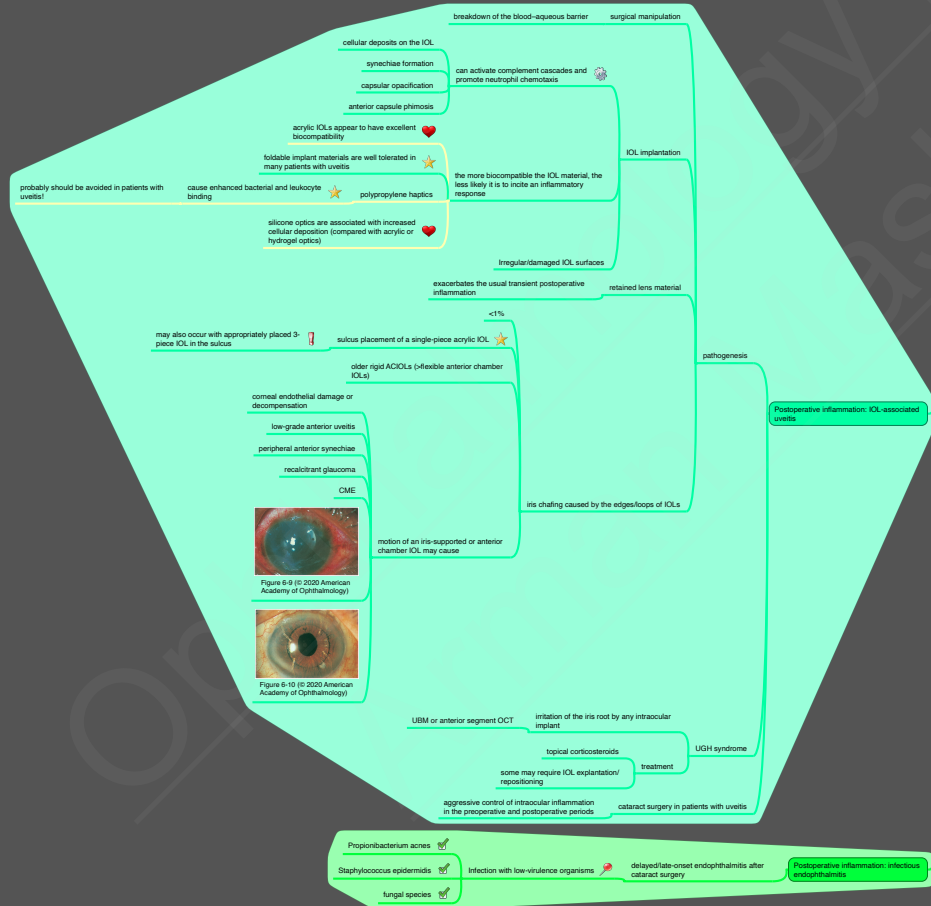


Figure 6-9 (© 2020 American Academy of Ophthalmology)

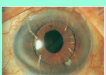

Figure 6-10 (© 2020 American Academy of Ophthalmology)

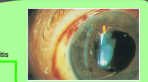


Figure 6-7 (© 2020 American Academy of Ophthalmology)

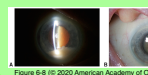


Figure 6-8 (© 2020 American Academy of Ophthalmology)

### Lens-associated uveitis

