9.6.12. Posterior Uveitis (V): White Dot Syndromes (I)

Birdshot uveitis

- birdshot chorioretinopathy
- epidemiology
  - F>M
    - white women of northern European descent
  - past the fourth decade of life
  - highly correlated with the HLA-A29 gene
    - sensitivity of 96%
    - specificity of 93%
    - increased (224x) relative risk
    - 7% of the general population are HLA-A29 (+)
      - HLA-A29 is confirmatory rather than diagnostic!
- symptoms
  - blurred vision
  - floaters
  - nyctalopia
  - disturbance of color vision
  - unusual peripheral visual phenomena
    - pinwheels
    - sparkles
    - flickering lights
  - visual complaints out of proportion to visual acuity
- clinical presentation
  - multifocal, hypopigmented, ovoid, cream-colored lesions (50–1500 μm)
    - nasal and radial distribution emanating from the optic nerve
      - 
        Figure4 6-22 (© 2020 American Academy of Ophthalmology)
    - may not be readily apparent at first
    - frequently follow the underlying choroidal vessels
    - at the level of the choroid and RPE
    - postequatorial
  - minimal or absent anterior uveitis
  - varying degrees of vitritis
  - CME
  - retinal vasculitis
  - optic nerve head inflammation
  - late complications
    - optic atrophy
    - epiretinal membrane
    - CNV
      - rare
- lab evaluation
  - fluorescein angiography
    - early disease
      - initial hypofluorescence with subtle late staining
      - useful in identifying signs of active inflammation
        - retinal vasculitis
          -
            Figure 6-23 (© 2020 American Academy of Ophthalmology)
        - CME
          -
            Figure 6-24 (© 2020 American Academy of Ophthalmology)
        - optic nerve head leakage
        - does not typically highlight the lesions
    - late disease
      - hypopigmented lesions do not show transmission defects
      - loss of pigment concurrent with loss of choriocapillaris
  - indocyanine green angiography
    - multiple hypofluorescent spots
      - 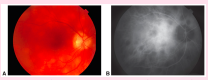
        Figure 6-25 (© 2020 American Academy of Ophthalmology)
    - more numerous than on clinical examination or FA
  - fundus autofluorescence imaging
    - hypoautofluorescence
    - more numerous and not uniformly correspondent with the birdshot lesions
    - placoid macular hypoautofluorescence
      - important predictor of central vision loss
        - 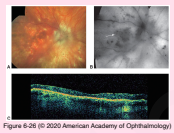
          Figure 6-26 (© 2020 American Academy of Ophthalmology)
  - OCT imaging
    - patchy or diffuse loss of photoreceptors
      - macular thinning
    - macular edema
- differential diagnostic
  - pars planitis
  - VKH syndrome
  - sympathetic ophthalmia
  - OHS
  - intraocular lymphoma
  - sarcoidosis
- management
  - natural course
    - insidiously progressive (chronic)
      - progressive worsening of the visual field
      - abnormal electroretinogram (ERG) with extended follow-up
      - majority of patients require treatment
    - self-limited
      - a subset of patients do well without treatment
      - any patient who is not treated should be monitored closely
  - monitoring of disease course
    - full-field ERG
      - 30-Hz flicker implicit time
      - scotopic b-wave amplitudes
      - more useful for monitoring disease course than changes in visual acuity or funduscopic appearance
    - Goldmann/automated visual field (30-2)
      - more useful for monitoring disease course than changes in visual acuity or funduscopic appearance
  - systemic corticosteroids
    - typically incompletely responsive to corticosteroids alone
    - extended treatment is anticipated in most patients
  - early introduction of corticosteroid-sparing IMT
    - low-dose cyclosporine (2–5 mg/kg/day)
    - mycophenolate mofetil
    - azathioprine
    - methotrexate
    - TNF-α inhibitors
    - intravenous polyclonal immunoglobulin
  - periocular/intravitreal corticosteroid injections
    - adjunctive therapy for CME and inflammatory recurrences
  - intravitreal fluocinolone acetonide implant
    - systemic therapy not tolerated or has failed
  - ≥88% of patients maintain vision with aggressive, long-term control of inflammation

Inflammatory Chorioretinopathies of Unknown Etiology

- See Table 6-2
- white dot syndromes
  - group of inflammatory disorders with discrete, multiple, well-circumscribed, yellow-white lesions at the level of the retina/outer retina/RPE/choriocapillaris or choroid during some phase of their course
- epidemiology
  - < 50 years except
    - birdshot uveitis
    - serpiginous choroiditis
  - female predominance
    - MEWDS
    - birdshot uveitis
    - multifocal choroiditis and panuveitis
    - punctate inner choroiditis (PIC)
    - subretinal fibrosis and uveitis syndrome
    - acute zonal occult outer retinopathy
    - except
      - APMPPE — M=F
      - serpiginous choroidopathy — M=F
- etiology
  - autoimmune/inflammatory
    - increased prevalence of systemic autoimmunity both in patients with WWS and their first/second-degree relatives
    - inherited immune dysregulation that predisposes to autoimmunity
  - infectious cause
  - unknown
- prodromal viral syndrome
  - APMPPE
  - MEWDS
- bilateral +- asymmetrical
  - with the exception of
    - multiple evanescent white dot syndrome [MEWDS]
    - ARPE
- presenting symptoms
  - photopsias
  - blurred vision
  - nyctalopia
    - birdshot
  - floaters
  - visual field loss contiguous with the blind spot
- differential diagnosis
  - infectious entities
    - syphilis
    - diffuse unilateral subacute neuroretinitis (DUSN)
    - ocular histoplasmosis syndrome (OHS)
  - noninfectious entities
    - sarcoidosis
    - sympathetic ophthalmia
    - Vogt-Koyanagi-Harada (VKH) syndrome
    - intraocular lymphoma

Ophthalmology Mind Maps/Arman Mashayekhi, MD