12.9.1. Central Serous Chorioretinopathy (CSC)

BCSC 2020-2021

- **pathogenesis**
  - hyperpermeability of choroid (choriocapillaris) — leakage at level of RPE
  - leakage into subretinal space
  - impaired fluid removal from subretinal space
- **demographics**
  - healthy
  - 35-55 years
  - M>F — 3:1
  - no racial predilection
- **etiology**
  - personality type
    - stress
    - tense driven personality (type A)
  - elevated levels of corticosteroids
    - endogenous hypercortisolism (Cushing syndrome)
    - corticosteroid administration — systemic
      - not intravitreal
  - systemic hypertension
  - sleep apnea
  - psychopharmacologic medications
  - pregnancy
  - +- bilateral — aymmetric
- **clinical**
  - symptoms — suggen onset
    - blurred vision
    - dim vision
    - micropsia
    - metamorphopsia
    - paracentral scotoma
    - decreased color vision
    - prolonged afterimages
  - visual acuity
    - 20/20-20/200 — usually >20/30
    - improves with hyperopic correction
  - acute findings
    - serous detachment of sensory retina
      - round or oval
      - localized — often involves fovea
    - small whitish subretinal precipitates
    - serous RPE detachment
      - under superior half of serous retinal detachment
      - without serous retinal detachment
    - gray-white feather-edge subretinal material — fibrin
  - chronic findings
    - granular RPE pigmentation
    - widespread shallow detachment
    - photoreceptors atrophy
    - multiple small leaks on IVFA
    - RPE atrophic areas
      - evidence of prior episodes
      - run-off/guttering
      - pachychoroidal pigment retinopathy
        - thick choroid
        - RPE alterations
        - no serous retinal detachment
  - CNV
    - in ≤ 20% of patients >50 yr — even without laser
    - easy to detect with OCT angiography
    - in 2% of eyes treated with photocoagulation
    - in the immediate postoperative period in 2% of eyes after photocoagulation

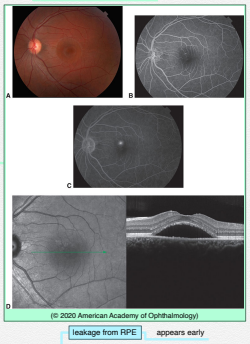

(© 2020 American Academy of Ophthalmology)

- **fluorescein angiography**
  - leakage from RPE — appears early
  - patterns
    - dot form
      - expansile dot
        - most common
        - +- multiple
        - early phase of angiogram — focal leak through RPE — dot
        - late phase of angiogram — pooling of dye in subretinal space — 10-15 min
    - smokestack form
      - tree-shaped
      - uncommon — 10%
    - diffuse
      - extensive gravity-dependent serous retinal detachment
      - extensive RPE changes
      - without obvious leakage point

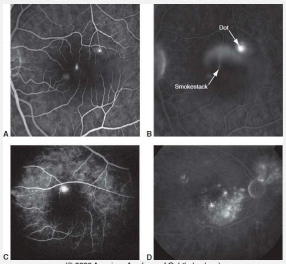

(© 2020 American Academy of Ophthalmology)

- **other imaging modalities**
  - OCT
    - neurosensory RD

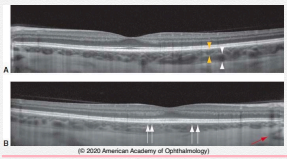

(© 2020 American Academy of Ophthalmology)

    - EDI-OCT
      - thick choroid

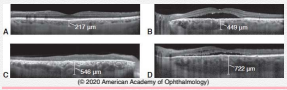

(© 2020 American Academy of Ophthalmology)

      - posterior loculation of fluid in deep choroid
        - in areas where thickening is most prominent
    - CNV
      - irregular wavy, shallow elevation of the RPE by a layer of material with heterogeneous reflectivity
  - fundus autofluorescence

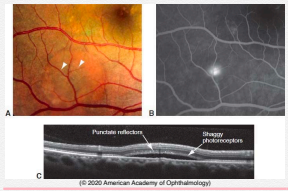

(© 2020 American Academy of Ophthalmology)

    - white dots under retina are macrophages with fluorophores from phagocytized outer segments
    - accumulation of shed outer segments in subretinal space

(© 2020 American Academy of Ophthalmology)

    - RPE defects — focal hypoautofluorescence
    - chronic CSC — descending tracts
    - poorer vision — lower levels of central macular autofluorescence
  - indocyanine green angiography

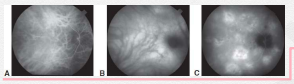

    - choroidal vascular hyperpermeability
    - CNV
    - choroidal vascular abnormalities
      - filling delays in choroidal arteries & choriocapillaris
      - venous dilation
      - hyperpermeability of choroidal vessels
      - hyperfluorescent patches
        - multifocal
        - appear early
        - slowly enlarge during angiogram
        - less prominent in late views
      - washout pattern
        - unchanged during clinically inactive phases
    - helps to differentiate atypical diffuse CSC in older patients from
      - occult CNV
      - polypoidal choroidal vasculopathy
  - OCT angiography
    - detecting type 1 CNV

- **differential diagnosis**
  - type 1 CNV
    - OCT demonstrates an irregular wavy, shallow elevation of the RPE by a layer of material with heterogeneous reflectivity
    - FA findings overlap with CSC
  - polypoidal choroidal vasculopathy (PCV)

- **natural course**
  - good visual prognosis except
    - chronic recurrent CSC
    - bullous CSC
  - spontaneous resolution — 80-90%
    - within 3-4 months
    - visual recovery within 1 year
    - residual symptoms
      - mild metamorphopsia
      - faint scotomata
      - abnormal contrast sensitivity
      - mild color vision deficitts
      - permanent diminished visual acuity
  - recurrence — 40-50%

- **treatment**
  - laser photocoagulation
    - more rapid resorption of subretinal fluid — 5 weeks vs 23 weeks
    - no improvement in final visual acuity
    - no decrease in recurrence rate
    - no effect on choroidal thickness
    - sub-threshold laser photocoagulation
  - photodynamic therapy with verteporfin
    - reduces or eliminates subretinal fluid
    - few complications — atrophy — 4%
    - recurrence after successful PDT is rare
    - decreases choroidal thickness and reduces choroidal vascular hyperpermeability
    - standard (600 mW/cm2) to reduced fluence (300 mW/cm2)
  - medical treatment
    - mineralocorticoid receptor antagonists
      - eplerenone
      - spironolactone — resolution of subretinal fluid in 25%

Ophthalmology Mind Maps/Arman Mashayekhi, MD