8.10.7. Ectatic Disorders (II)

Pellucid Marginal Degeneration

- uncommon
- nonhereditary
  - similar to keratoconus & keratoglobus
- clinical presentation
  - 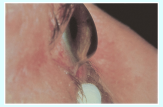
    Figure 10-29 (© 2020 American Academy of Ophthalmology)
  - bilateral
  - diagnosis between 20-40 years of age
  - inferior corneal steepening
    - Similar to KCS
  - inferior, peripheral corneal thinning
    - "lobster claw" pattern
      - 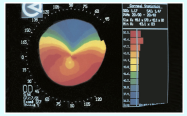
        Figure 10-30 (© 2020 American Academy of Ophthalmology)
  - decreased vision
    - high irregular astigmatism
  - ± posterior stromal scarring within thinned area
  - absence of inflammation
  - no vascularization or lipid deposition
  - acute hydrops
    - has been reported
  - spontaneous corneal perforation
    - rare
  - at times, a clear distinction between pellucid marginal degeneration and keratoconus is not possible
    - keratoconus
      - protrusion is at the point of maximal thinning
    - pellucid marginal degeneration
      - protrusion is above area of maximum thinning
- treatment
  - contact lenses
    - lens fitting is more difficult in pellucid marginal degeneration than in keratoconus
    - hybrid (gas-permeable contact lenses with a soft lens "skirt")
    - scleral lenses
  - PK
    - grafts tend to be large and close to the limbus
      - technically more difficult
      - graft more prone to rejection
  - wedge resection
  - lamellar tectonic grafts
  - collagen crosslinking

Keratoglobus

- epidemiology
  - very rare
    - similar to keratoconus & PMD
  - not hereditary
  - associations
    - blue sclerae
    - Ehlers-Danlos syndrome type VI
    - may represent a defect in collagen synthesis
    - unlike keratoconus, keratoglobus is not associated with atopy and hard contact lens wear
- pathology
  - absent/fragmented Bowman layer
  - thinned stroma with normal lamellar organization
  - thin Descemet membrane
    - in contrast to keratoconus and pellucid marginal degeneration
- clinical presentation
  - present at birth
  - bilateral
  - globular corneal deformation
    - generalized thinning
      - in contrast to keratoconus, which has maximal thinning at or near the apex of the protrusion
    - especially in midperiphery
    - steep cornea
      - corneal curvature may be as steep as 50–60 D
    -
      Figure 10-31 (© 2020 American Academy of Ophthalmology)
  - very deep anterior chamber
  - iron lines/Fleischer rings, stress lines, and anterior scarring are not seen
  - corneal diameter may be slightly increased
  - corneal hydrops
    - can occur
    - spontaneous rupture of the Descemet membrane
  - spontaneous corneal rupture
    - has been reported
- treatment
  - spectacles
    - for high myopia
    - to prevent amblyopia
  - contact lenses
    - scleral lenses
  - PK
    - prognosis for PK is much poorer in keratoglobus than in other ectasias
  - lamellar tectonic graft followed by PK
  - protective eyewear

Ophthalmology Mind Maps/Arman Mashayekhi, MD