8.12.2. Degenerative Changes in the Cornea (I): Epithelial and Subepithelial Degenerations

Iron deposition

- related to abnormalities of tear pooling due to surface irregularities
  - 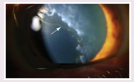
    Figure 12-7 (© 2020 American Academy of Ophthalmology)
  - See Table 12-3
- red-free or cobalt blue illumination before instilling fluorescein
  - Fleischer ring
    - keratoconus
    - useful in the diagnosis of mild or early cases of keratoconus
  - Hudson-Stähli line
    - junction of the upper two-thirds and lower one-third of the cornea
  - tear star
    - keratorefractive surgery
      - centrally in approximately 80% of patients

Calcific band keratopathy

- clinical presentation
  - fine, dustlike, basophilic deposits in the Bowman layer
  - peripherally in the 3- and 9-o'clock positions
    - can progress to horizontal band of dense calcific plaques across the interpalpebral zone of the cornea
  - lucid interval
  - fibrous pannus
    - if silicone oil is responsible
  - 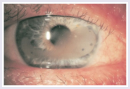
    Figure 12-8 (© 2020 American Academy of Ophthalmology)
- types
  - idiopathic
  - secondary
    - chronic ocular disease (inflammatory, phthisis bulbi)
    - hypercalcemia (hyperparathyroidism, vitamin D toxicity, milk-alkali syndrome, sarcoidosis, or other systemic disorders)
    - hereditary transmission (primary hereditary band keratopathy)
    - elevated serum phosphorus level with normal serum calcium (renal failure)
    - chronic exposure to mercurial vapors or to mercurial preservatives (phenylmercuric nitrate or acetate) in ophthalmic medications
      - mercury causes changes in corneal collagen that result in the deposition of calcium
    - silicone oil instillation in an aphakic eye
- deposition of urates in the cornea
  - brown, unlike the gray-white calcific deposits
  - gout or hyperuricemia
- management
  - workup
    - serum electrolytes
      - high calcium or high phosphorus
    - urinalysis
  - underlying conditions should be treated
  - chelation with neutral solution of disodium ethylenediaminetetraacetic acid (EDTA)
    - 0.5%–1.5%
    - remove overlying epithelium
    - warm to speed up the chemical chelation
    - cylindrical tube
      - acting as a reservoir to confine the chelating solution to the desired treatment area
    - gentle surface agitation
    - scraping should be gentle so as to prevent damage to the Bowman layer
    - neither EDTA nor scraping will remove fibrous pannus
    - can recur
  - PTK using an excimer laser is not advised
    - could produce a severely irregular surface
    - for residual opacification after initial EDTA

Age-Related (Involutional) Changes

- cornea gradually becomes
  - flatter in the vertical meridian
  - thinner
  - slightly less transparent
- refractive index increases
- Descemet membrane becomes thicker
  - 3 µm at birth to 10 µm in adults
- occasional peripheral endothelial guttae
  - Hassall-Henle bodies
- attrition of corneal endothelial cells
  - loss of about 100,000 cells during the first 50 years of life
    - 4000 cells/mm2 at birth
    - 2500–3000 cells/mm2 in older adults
    - 0.6% decrease per year

Coats white ring

- area of discrete gray-white dots
  - small (1 mm or less in diameter)
  - circle or oval-shaped
  - superficial stroma
  -
    Figure 12-5 (© 2020 American Academy of Ophthalmology)
- iron-containing fibrotic remnants of a metallic foreign body
- once these lesions mature they do not change
  - therapy with corticosteroids/anti-inflammatory agents is not indicated

Spheroidal degeneration

- translucent, golden brown, spheroidlike deposits
  - cornea +- conjunctiva
  - subepithelium, Bowman layer, or superficial stroma
  - 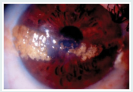
    Figure 12-6 (© 2020 American Academy of Ophthalmology)
- types
  - primary spheroidal degeneration
    - unrelated to the coexistence of other ocular disease
    - bilateral
    - nasal and temporal cornea
      - with age, can extend onto the conjunctiva in the interpalpebral zone
      - rarely extends across the interpalpebral zone of the cornea
      - noncalcific band-shaped keratopathy
  - secondary spheroidal degeneration
    - ocular injury or inflammation
    - near corneal scarring or vascularization
- extracellular, proteinaceous, hyaline deposits with characteristics of elastotic degeneration
  - composition is not lipid!
- management
  - no medical therapy is of much value
  - lubrication
  - central involvement
    - superficial keratectomy
    - phototherapeutic keratectomy
      - excimer laser
  - recurrence after conjunctival resection is common

Ophthalmology Mind Maps/Arman Mashayekhi, MD