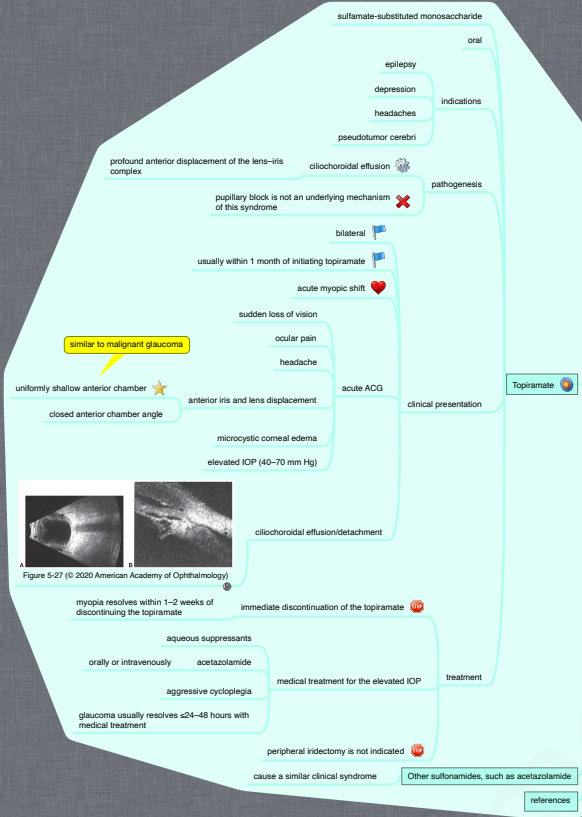
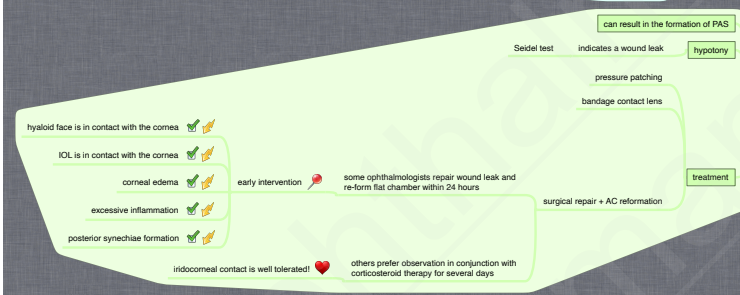

10.5.6. Angle-Closure Glaucoma (VI): Secondary Angle Closure Without Pupillary Block (II)

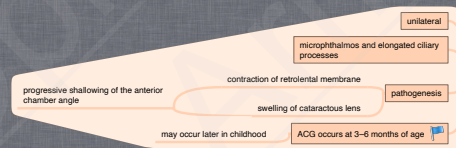
Drug-Induced Secondary Angle-Closure Glaucoma



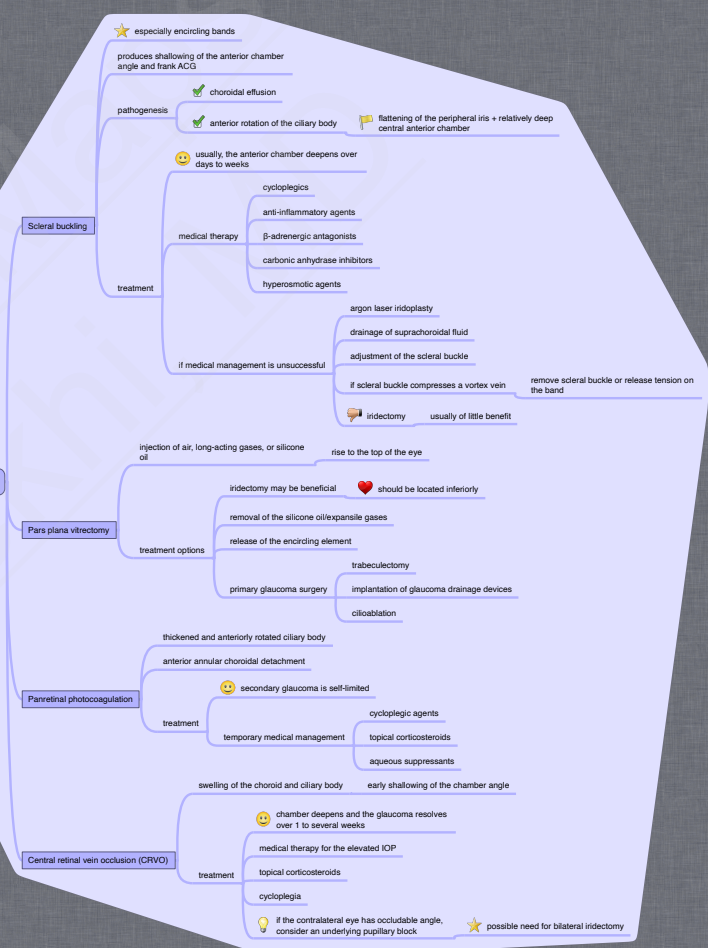
Flat Anterior Chamber



Persistent Fetal Vasculature



Retinal Surgery and Retinal Vascular Disease



Nanophthalmos

