9.7.5. Infectious Ocular Inflammatory Diseases (V): EBV/LCMV

Lymphocytic choriomeningitis virus (LCMV)

- single-stranded RNA virus
  - Arenaviridae family
  - fetal teratogen
  - rodents are the natural hosts
    - transmission
      - airborne
      - contaminated food by infected rodent excreta
      - bite of an infected animal
- symptomatic maternal illness
  - maternal viremia
    - 2/3
  - transmission earlier in gestation results in more serious sequelae
- systemic findings
  - macrocephaly
  - hydrocephalus
  - intracranial calcifications
    - periventricular
  - seizures
  - mild cognitive impairment
  - neurologic abnormalities
- ocular manifestations
  - optic atrophy
  - strabismus
  - nystagmus
  - macular and chorioretinal peripheral scarring
    - similar to that of congenital toxoplasmosis
- differentiation from congenital toxoplasmosis
  - serologic testing of the mother and the infant
    - Immunofluorescent antibody tests
    - Western blot
    - ELISA
    - IgM and IgG antibodies
  - pattern of intracerebral calcifications
    - toxoplasmosis
      - diffuse
    - congenital LCMV
      - periventricular distribution

Epstein-Barr virus (EBV)

- similar to herpes viruses
- double-stranded DNA virus
  - complex capsid and envelope
  - tropism for B lymphocytes
    - only cells known to have surface receptors for the virus
  - very high seroprevalence of EBV (90%) in the adult population
- diseases
  - infectious mononucleosis (IM)
  - Burkitt lymphoma (especially among African children)
  - nasopharyngeal carcinoma
  - Hodgkin disease
  - Sjögren syndrome
- anterior segment manifestations
  - cataract
    - congenital EBV infection
  - mild, self-limiting follicular conjunctivitis
    - early in the course of acquired IM
  - less frequently reported anterior ocular manifestations
    - epithelial or stromal keratitis
    - episcleritis
    - bilateral, granulomatous anterior uveitis
    - dacryoadenitis
    - cranial nerve palsies
    - Parinaud oculoglandular syndrome
- posterior segment manifestations
  - isolated optic disc edema and optic neuritis
  - macular edema
  - retinal hemorrhages
  - retinitis

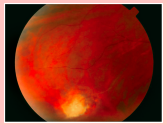

Figure 7-11 (© 2020 American Academy of Ophthalmology)

  - punctate outer retinitis
  - choroiditis
  - multifocal choroiditis and panuveitis (MCP)
  - pars planitis and vitritis
  - progressive subretinal fibrosis
  - secondary choroidal neovascularization
  - ARN
  - association between these findings and EBV infection is not well established
- treatment
  - ocular disease is self-limiting
    - does not require treatment
  - anterior uveitis
    - topical corticosteroids and cycloplegia
  - posterior segment inflammation
    - systemic corticosteroids
  - efficacy of systemic antiviral therapy for EBV infection has not been established
    - consider for necrotizing retinitis/ARN

Ophthalmology Mind Maps/Arman Mashayekhi, MD