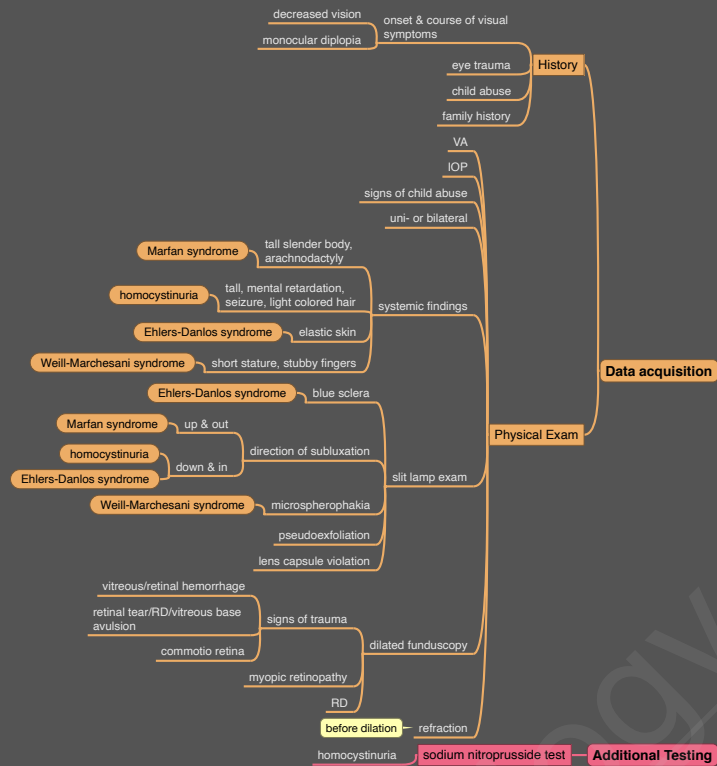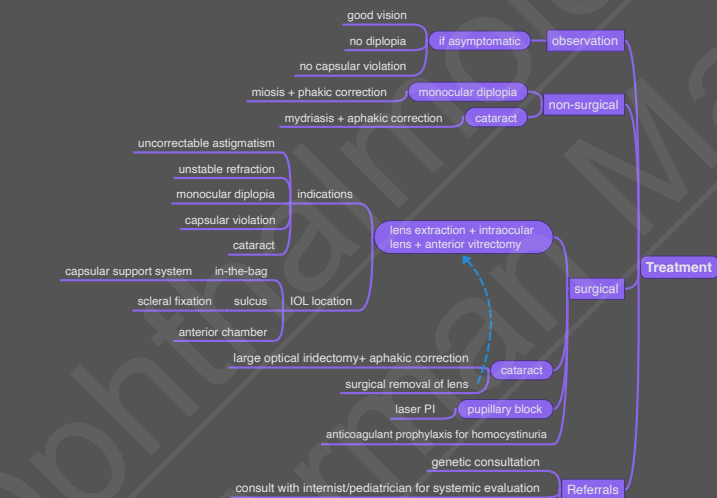
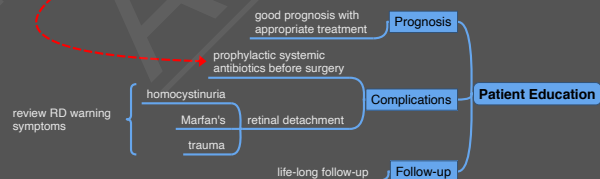


Additional Testing

Assessment

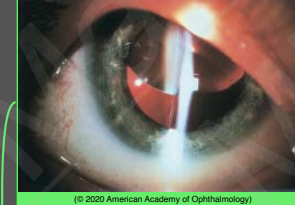


Patient Education



Case Description

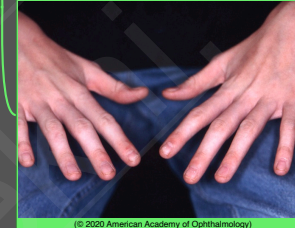young child with tall stature and long fingers complains of decreased vision of his right eye



slit lamp photograph shows upward subluxation of the lens

(© 2020 American Academy of Ophthalmology)

Image Description



examination shows long and slender fingers

(© 2020 American Academy of Ophthalmology)

Differential Diagnosis

