4.13.3. Eyelids (III): Neoplasia (I)

Basal cell carcinoma

- demographics
  - 90% most common malignant neoplasm of eyelids
  - sites
    - lower lid
    - risk of orbital invasion: medial canthus
  - predisposing conditions
    - fair-skinned
    - blue-eyed
    - red-haired or blond
    - seen with increasing frequency in younger patients: middle-aged and elderly persons
    - English, Irish, Scottish, or Scandinavian ancestry
    - prolonged sun exposure during the first 2 decades of life
    - cigarette smoking
- types
  - clinical
    - nodular type
      - elevated lesion
        - ulceration
        - pearly raised rolled edges
      - slowly enlarging

Figure 13-17 (© 2020 American Academy of Ophthalmology)

    - morpheaform
      - flat-slightly depressed pale yellow indurated plaque
      - infiltrative growth pattern
      - histology
        - no peripheral palisading
        - thin cords that radiate peripherally
        - surrounding stroma may show proliferation of connective tissue into a pattern of fibrosis

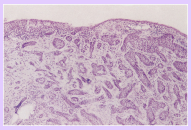
Figure 13-18 (© 2020 American Academy of Ophthalmology)

    - multicentric
    - pigmented
    - rarely metastasize: local spread
- histology
  - cohesive tumor cell islands
    - only hair-bearing tissue: originates from stratum basale/germinativum
    - bland monomorphous nuclei + high N/C ratio
    - nuclear palisading of peripheral cell layer
    - clear space surrounds the islands
  - histologic patterns
    - keratotic (hair follicle)
    - squamous (metatypical)
    - sebaceous
    - adenoid
    - eccrine (syringoid)
    - morphea (sclerosing): thin cords/strands in fibrotic stroma
- treatment
  - complete excision with surgical margin control

Squamous cell carcinoma

- demographics
  - 10-40 x less common than BCC
  - solar damaged skin
    - lower lid>upper lid
    - proportion of upper lid SCC>proportion of upper lid BCC
- clinical
  - diverse appearance
    - ulcer
    - plaque
    - fungating
    - nodular
  - 20% regional lymph node metastasis
- histology
  - atypical squamous cells
    - variable differentiation
      - moderately differentiated
        - keratin formation
        - fibrotic reaction in dermis
        - extend beyond basement membrane
        - well-differentiated
      - poorly differentiated
    - intercellular bridges
  - perineural invasion
  - lymphatic invasion
- treatment
  - complete excision with surgical margin control

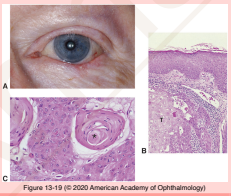
Figure 13-19 (© 2020 American Academy of Ophthalmology)

Capillary neoplasm

- appear at/shortly after birth
- bright red
- grow over weeks to months
- involute by school age
- treat if interfere with vision (amblyopia)
  - ptosis
  - astigmatism
- histology
  - early lesions
    - solid nests of plump endothelial cells: very cellular
    - little vascular luminal formation
  - established lesions
    - well-developed flattened endothelium-lined capillary channels
  - involuting lesions
    - increased fibrosis
    - hyalinization of capillary walls
    - luminal occlusion

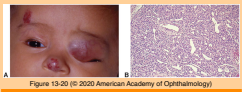
Figure 13-20 (© 2020 American Academy of Ophthalmology)

Seborrheic keratosis

- clinical
  - middle age
  - "stuck-on" papule
  - dome-shaped to verrucoid
  - pink to brown
- systemic association: malignancy (gastrointesinal malignancy)
  - sudden onset of multiple seborrheic keratosis
    - Leser-Trelat sign
    - evolving acanthosis nigricans
- histology
  - hyperkeratosis
  - acanthosis: proliferation of polygonal or basaloid squamous cells without dysplasia
  - papillomatosis
  - pseudohorn cysts
    - concentrically laminated collections of surface keratin in acanthotic epithelium
    - are in fact crevices/infoldings of surface epidermis
  - melanin phagocytosis by keratinocytes: brown color

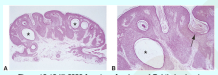
Figure 13-12 (© 2020 American Academy of Ophthalmology)

  - inverted follicular keratosis (irritated seborrheic keratosis)
    - squamous eddies
      - nonkeratinizing squamous epithelial whorling
      - no pseudohorn cysts
    - clinically appear as cutaneous horn

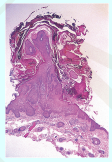
Figure 13-13 (© 2020 American Academy of Ophthalmology)

- Eyelid neoplasms in association with systemic malignancies
  - Muir-Torre syndrome
    - keratoacanthoma; sebaceous adenoma/carcinoma
    - autosomal dominant; visceral (colon) carcinoma
  - Cowden disease
    - Multiple trichilemmomas
    - Autosomal dominant; fibrous hamartomas (breast, thyroid, GI); breast carcinoma
  - Basal cell nevus syndrome (Gorlin syndrome)
    - multiple basal cell carcinomas
    - autosomal dominant; medulloblastoma, fibrosarcoma
    - skeletal anomalies
      - mandible
      - maxilla
      - vertebrae

Keratoacanthoma

- clinical
  - dome-shaped nodule: ≤ 2.5 cm
  - keratin-filled central crater
  - rapid growth: over weeks to months
  - spontaneous resolution: over several months: depressed scar
- histology
  - cup-shaped proliferation of well-differentiated squamous cells
    - variant of well-differentiated squamous cell carcinoma
    - irregularly configured nests/strands
    - chronic inflammatory response
  - undermine adjacent normal epidermis
  - deep aspect
    - +- mitotic activity
    - +- nuclear atypia
  - if definite invasion, lesion should be considered a well-differentiated keratinizing squamous cell carcinoma
- treatment

Figure 13-14 (© 2020 American Academy of Ophthalmology)

Actinic keratosis

- clinical
  - erythematous scaly macules/papules: few mm to 1 cm
  - hyperkeratotic type: cutaneous horn
  - hyperpigmented type: simulates lentigo maligna
  - middle age
  - sun-exposed skin
  - precancerous: squamous cell carcinoma: 0.5-3% metastasis
- histology
  - epidermis
    - hyperkeratosis
    - parakeratosis
    - dyskeratosis
    - mitotic figures
    - cellular atypia

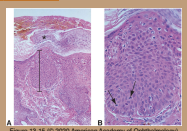
Figure 13-15 (© 2020 American Academy of Ophthalmology)

  - dermis
    - solar elastosis of underlying dermis
      - fragmentation/clumping/loss of eosinophilia of dermal collagen

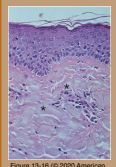
Figure 13-16 (© 2020 American Academy of Ophthalmology)

    - chronic inflammatory infiltrate
- treatment
  - shave biopsy not including the base is contraindicated!

Ophthalmology Mind Maps/Arman Mashayekhi, MD