4.13.5. Eyelids (V): Neoplasia (III): Melanocytic Neoplasms

- **Melanocytic nevi**
  - congenital
    - larger
      - giant congenital melanocytic nevi
        - >20 cm
    - risk of melanoma proportional to nevus size
      - close follow-up
      - excision
    - kissing nevus
      - before in utero separation of upper and lower lids

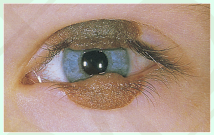

Figure 13-26 (© 2020 American Academy of Ophthalmology)

  - nevus cells
    - round
    - cluster together in nests
    - variable melanin pigment
    - multinucleated giant melanocytes
    - interspersed adipose tissue
      - older nevi
  - cytomorphologic evolution
    - superficial portion of nevus
      - polygonal/epithelioid
        - type A nevus cells
    - midportion of nevus
      - smaller with less cytoplasm (resemble lymphocytes)
        - type B nevus cells
    - deep portion of nevus
      - spindled (resemble Schwann cells)
        - type C nevus cells
  - nevus evolution
    - junctional nevus
      - macular (flat) lesion
      - nests of melanocytes along epidermal-dermal junction

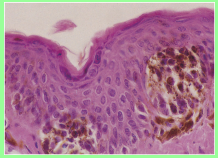

Figure 13-27 (© 2020 American Academy of Ophthalmology)

      - differential diagnosis
        - ephelis (freckle)
          - basal epithelial layer contains the pigment
    - compound nevus
      - adolescence
      - elevated
      - increased pigmentation
      - nevus cells begin to migrate into superficial dermis

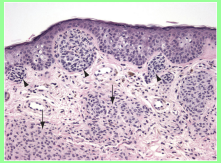

Figure 13-28 (© 2020 American Academy of Ophthalmology)

    - intradermal nevus
      - adulthood
      - junctional component disappears

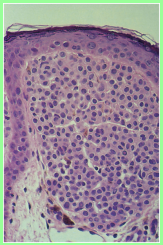

Figure 13-29 (© 2020 American Academy of Ophthalmology)

- **cutaneous melanoma**
  - atypical nevi
    - Spitz nevus
      - develop in late childhood/adolescence
      - ≤1 cm
        - larger
      - tan-pink color
      - histology
        - compound nevi
        - nuclear/cytoplasmic enlargement & pleomorphism
        - lack atypical mitotic figures, intraepidermal migration, lack of maturation
    - dysplastic nevus
      - >0.5 cm
      - irregular margins
      - irregular pigmentation
      - cytologic atypia
        - nuclear enlargement
        - hyperchromasia
        - prominent nucleoli
      - multiple dysplastic nevi
        - higher risk of melanoma
        - +- genetic susceptibility
          - examine family members
  - clinical
    - rare
    - origin
      - de novo
      - preexisting nevus
    - features associated with dysplastic nevus
    - elevated/indurated mass
    - prognosis
      - depth of invasion (Breslow depth)
    - metastasis
      - regional lymph nodes first
  - histology
    - histologic subtypes
      - lentigo maligna
        - most common type on eyelids
        - face of elderly patients
        - long preinvasive phase
        - basal layer of epidermis
        - outer sheaths of hair shafts
      - acral-lentiginous
        - involves extremities
        - similar to lentigo maligna but also involves more superficial epidermis
      - superficial spreading
        - most common type
        - all levels of epidermis (pagetoid pattern)
      - nodular
        - vertical growth pattern
    - pagetoid intraepidermal spread
    - except nodular type
      - cytologic atypia
      - atypical mitotic figures
      - lack of maturation in deeper portions
      - bandlike lymphocyte host response along the base

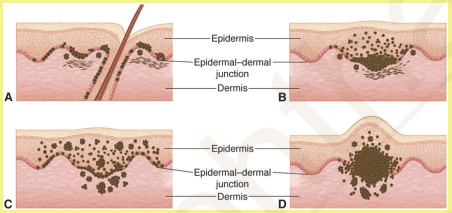

Figure 13-30 (© 2020 American Academy of Ophthalmology)
A. Lentigo maligna melanoma, B. Acral lentiginous melanoma, C. Superficial spreading melanoma, D. Nodular melanoma

Ophthalmology Mind Maps
Arman Mashayekhi, MD

Ophthalmology Mind Maps/Arman Mashayekhi, MD