Vitreoretinal Interface Diseases (1)

Vitreomacular Traction Diseases

- abnormalities that arise from focal or broad vitreomacular adhesions in the presence of detaching or otherwise detached posterior vitreous
- vitreomacular adhesion (VMA) 1
  - posterior hyaloid is abnormally adherent to the macula
  - does not cause visual symptoms
  - size
    - .<1500 µm — focal
    - >1500 µm — broad
- vitreomacular traction (VMT) syndrome 2
  - VMA + vitreous detachment
    - tractional foveal distortion
    - tractional foveal detachment
    - cystic edema
  - symptoms
    - complaints of poor vision out of proportion to measured visual acuity
    - decreased visual acuity
    - metamorphopsia
  - angiography
    - leakage of fluorescein from macular vessels and optic nerve
  - OCT

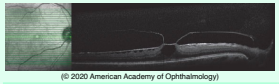

(© 2020 American Academy of Ophthalmology)

  - course
    - long term chronic traction is harmful
    - particularly when
      - cystic edema
      - vision is affected
    - spontaneous separation
      - 50%
      - less if
        - associated ERM
        - adhesion is broad
  - treatment
    - pars plana vitrectomy with membrane peeling
      - highly successful
    - intravitreal injection of ocriplasmin
      - recombinant protease
        - active against fibronectin and laminin
      - success rate
        - 26.5% (ocriplasmin) vs 10.1% (placebo)
        - 33.6% for VMT< 1500 µm
      - side effect
        - permanent visual loss with electroretinogram (ERG) changes
          - rare
          - disruption of the interphotoreceptor matrix
- macular hole 3

Epiretinal Membrane

- Pathogenesis & Histology
  - transparent, avascular, fibrocellular membrane on inner retinal surface adherent to ILM
  - posterior vitreous detachment or schisis in almost all eyes
  - schisis leaves variable portions of posterior cortical vitreous attached to macula
    - allows cells to proliferate
      - retinal glial cells (astrocytes and Müller cells)
      - RPE cells
      - hyalocytes
      - myofibroblasts/fibroblasts
      - macrophages
- Demographics
  - most common after age 50 years
    - 2% after age 50 years
    - 20% after age 75 years
    - autopsy
  - M = F
  - 10%–20% bilateral — usually asymmetric
- Types
  - idiopathic
  - Secondary
    - abnormal vitreoretinal adhesions
    - inflammation
    - retinal bleeding
    - retinal detachment
- Clinical findings
  - generally located in central macula
  - mild sheen or glint on the retinal surface — *cellophane maculopathy*
  - opaque membrane with wrinkling/striae of retina
    - *macular puckering*
    - *preretinal macular fibrosis*
  - steepening fovea into a cylindrical depression — *"pseudohole"*
  - intraretinal hemorrhages
  - whitened patches of superficial retina
  - diffuse retinal thickening
  - increased vascular tortuosity in macula — straightening of the perimacular vessels

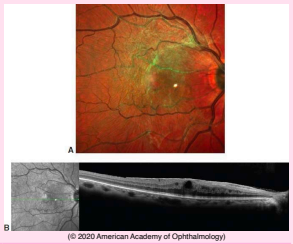

(© 2020 American Academy of Ophthalmology)

- OCT findings
  - highly reflective epiretinal layer
  - loss of the normal foveal contour
  - retinal thickening
  - cystoid retinal edema
  - irregularities of the inner retinal surface
  - shallow macular detachment
- Fluorescein angiography
  - staining of the optic nerve
  - capillary leakage in the central macula
- Course
  - often progresses
    - even after being stable
    - rate of progression and severity vary
  - spontaneous detachment — rare
- Treatment
  - observation
    - asymptomatic
    - visual acuity is good
  - vitrectomy
    - metamorphopsia
    - reduced visual acuity

Ophthalmology Mind Maps
Arman Mashayekhi, MD