# 8.9.1: Congenital Anomalies (I): Globe

See Table 9-1

## Cryptophthalmos

- forms
  - isolated
  - recessive syndromic
    - Fraser syndrome
      - acrofacial and urogenital malformations
      - +- cryptophthalmos
    - mutations in the FRAS1 gene
      - 4q21
      - encodes a putative extracellular matrix protein
- clinical presentation
  - usually bilateral
  - eyelids and associated structures of the brows and lashes fail to form (ablepharon)
    - 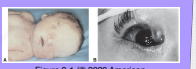
    - Figure 9-1 (© 2020 American Academy of Ophthalmology)
  - cornea is merged with the epidermis
  - conjunctiva is typically absent
  - anterior chamber, iris, and lens are variably formed or are absent
  - associated ocular findings
    - absence of the lacrimal glands and canaliculi
    - corneal and conjunctival dermoid
- pseudocryptophthalmos
  - eyelids and associated structures form but fail to separate (ankyloblepharon)
- treatment
  - surgical intervention
    - cosmesis
    - relief of pain from absolute glaucoma
  - pseudocryptophthalmos
    - eyelid reconstruction
    - fornix reconstruction

## Cryptophthalmos

- rare
- skin passes uninterrupted from the forehead, over the eye, to the cheek
  - blends in with the cornea, which is usually malformed
  -
  - Figure 17-3 (© 2020 American Academy of Ophthalmology)
- Fraser syndrome
  - autosomal recessive
  - partial syndactyly
  - genitourinary anomalies

## Microphthalmos

- small, disorganized globe
  -
  - Figure 9-2 (© 2020 American Academy of Ophthalmology)
  - often
    - cystic outpouching of the posteroinferior sclera
    - colobomatous defects of the iris, ciliary body, uvea, and optic nerve
- etiology
  - maternal infections
  - exposure to toxins and radiation
  - genetic abnormalities
    - most cases of nonsyndromic microphthalmos are sporadic
    - +- autosomal dominant, autosomal recessive, and X-linked forms
    - trisomies of almost every chromosome (typically, trisomy 13)
- systemic associations
  - intellectual disability
  - dwarfism
- associated ocular abnormalities
  - leukomas
  - anterior segment disorders
  - retinal dysplasia
  - colobomas
  - cysts
  - marked internal dysgenesis
  - persistent fetal vasculature (PFV)
  - small orbit
  - ptosis
  - blepharophimosis
  - cystic outpouching of the posteroinferior sclera
- management
  - cosmetic shell or contact lens
  - genetic counseling

## Nanophthalmos

- genetics
  - sporadic
  - hereditary
    - autosomal dominant
      - chromosome arm 11p
    - autosomal recessive
      - membrane-type frizzled protein (MFRP) gene
- clinical presentation
  - small, functional eye
    - relatively normal internal organization and proportions
  - short axial length (15–20 mm)
    - high degree of hyperopia (7–15 D)
  - high lens-to-eye volume ratio
    - crowded anterior segments
      - angle-closure glaucoma
  - thickened sclera
    - choroidal effusions or hemorrhage
  - steep corneal curvature
  - narrow palpebral fissures
  - strabismus
- management
  - angle-closure glaucoma
    - Laser iridotomy
    - peripheral laser iridoplasty
  - Cataract surgery
    - cataract surgery may be complicated by
      - exudative retinal detachment
      - uveal effusion/hemorrhage
    - high intraocular lens powers are required

## Blue Sclera

- generalized scleral thinning
  - increased visibility of the underlying uvea
- 2 syndromes
  - osteogenesis imperfecta type I
    - autosomal dominant
      - bone fragility
  - Ehlers-Danlos syndrome type VI
    - autosomal recessive
      - keratoglobus/keratoconus
      - joint hyperextensibility
      - severe kyphoscoliosis
      - cardiac anomalies
    - skin abnormalities
      - abnormal scarring
      - soft distensibility
      - easy bruisability
    - Ehlers-Danlos can be associated with angioid streaks
- differential diagnosis
  - ocular melanosis bulbi
  - rheumatoid arthritis
  - minocycline staining
- management
  - regular hearing evaluations after adolescence
  - postmenopausal women
    - long-term physical therapy to strengthen the paraspinal muscles
    - estrogen and progesterone replacement
    - adequate calcium and vitamin D intake

FAME

Ophthalmology Mind Maps/Arman Mashayekhi, MD