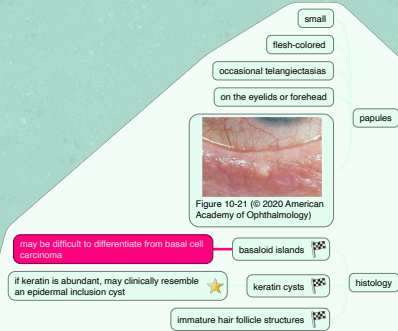


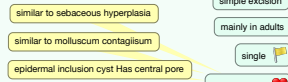
7.10.5. Eyelid Neoplasms (II): Benign Adnexal Lesions

Tumors of hair follicle origin

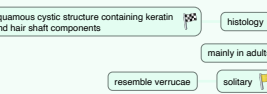
Trichoepithelioma



Trichofolliculoma



Trichilemmoma



Pilomatricoma

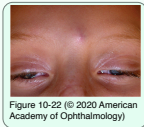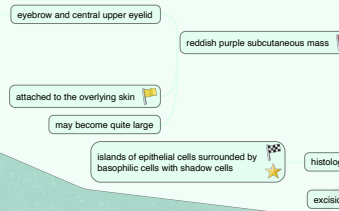
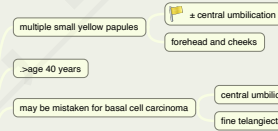


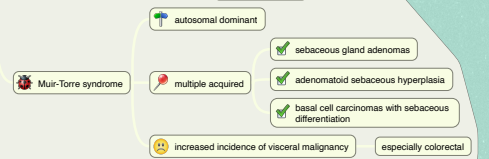
Figure 10-22 (© 2020 American Academy of Ophthalmology)

Lesions of oil gland origin

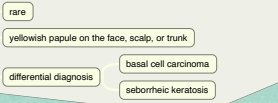
Chalazion and hordeolum



Sebaceous hyperplasia

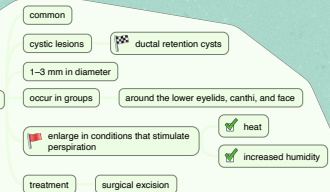


Sebaceous adenoma



Tumors of eccrine sweat gland origin

Eccrine hidrocystoma



Syringoma

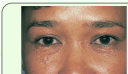
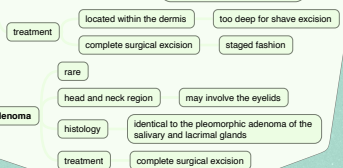


Figure 10-19 (© 2020 American Academy of Ophthalmology)

Pleomorphic adenoma



Tumors of apocrine sweat gland origin

Apocrine hidrocystoma

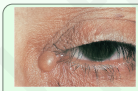
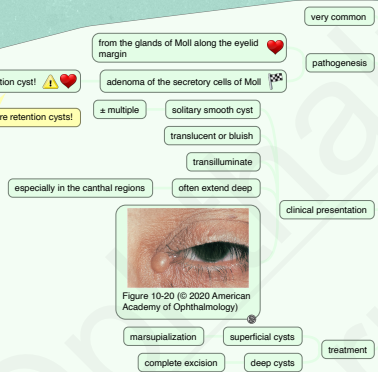


Figure 10-20 (© 2020 American Academy of Ophthalmology)

Cylindroma

