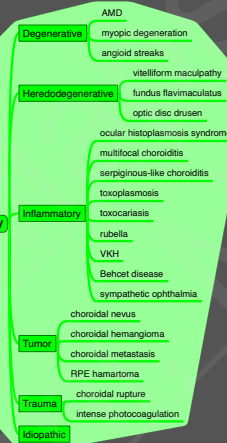
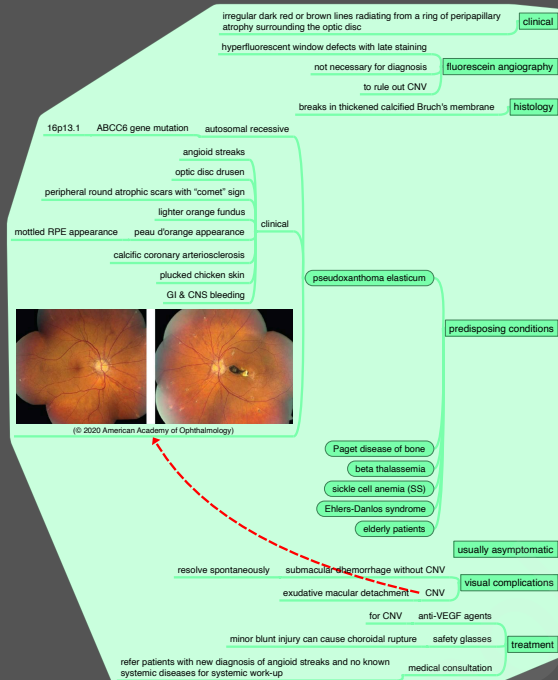


Neovascular AMD (V): Other Causes of CNV

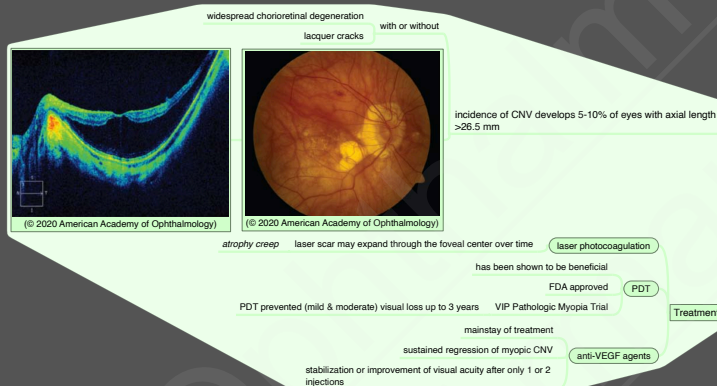
Conditions Associated with CNV



Angioid streaks



Pathologic myopia



Ocular Histoplasmosis Syndrome

