Central Retinal Vein Occlusion

Introduction

- pathogenesis
  - thrombosis of CRV at or posterior to lamina cribrosa
  - central retinal artery thickening --> turbulence, endothelial damage, and thrombus formation in CRV
- Risk factors & causes
  - >50 years old — 90%
    - patients with mild CRVO are generally younger
  - systemic associations (Eye Disease Case-Control Study)
    - systemic arterial hypertension
    - open angle glaucoma
    - diabetes mellitus — not a risk factor for BRVO
    - hyperlipidemia
    - hypercoagulability
      - hyperhomocysteinemia
      - protein S deficiency
      - protein C deficiency
  - medications
    - oral contraceptives
    - diuretics
  - vasculitis
    - sarcoidosis
    - SLE

Types

nonischemic (mild)

- "venous stasis retinopathy"
- visual acuity ≥20/200
- no or mild afferent pupillary defect
- mild visual field changes
- mild dilation & tortuosity of retinal veins
- dot & flame hemorrhages in all quadrants
- ± macular edema

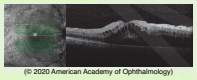

(© 2020 American Academy of Ophthalmology)

- ± mild optic disc swelling
- fluorescein angiography
  - prolonged retinal circulation time
  - breakdown of capillary permeability
  - minimal nonperfusion
- NVI — rare
- chronic changes
  - telangiectasia
  - microaneurysms
  - macular pigmentary changes
- young patients
- papillophlebitis
  - nonischemic CRVO
  - prominent disc edema

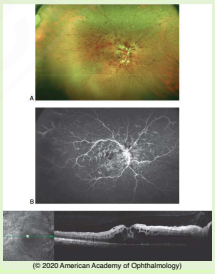

(© 2020 American Academy of Ophthalmology)

intermediate (indeterminate)

- 80% progress to severe form

ischemic (severe)

- ≥10 disc areas of capillary nonperfusion
- poor vision — ± premonitory symptoms of transient obscuration of vision before overt retinal manifestations
- afferent pupillary defect
- dense central scotoma
- peripheral field constriction
- marked venous dilation
- extensive 4-quadrant retinal hemorrhages
- retinal edema
- cotton wool spots
- fluorescein angiography
  - prolonged retinal circulation time
  - widespread capillary nonperfusion — ≥10 disc areas on a posterior pole view — >5 DD for BRVO
- ERG — decreased ERG bright-flash, dark-adapted b-wave to a-wave amplitude ratio
- poor visual prognosis
  - CVOS — VA>20/400 — 10%
  - prognosis better with anti-VEGF treatment
- NVI
  - ≤60%
  - 3-5 months after symptoms
- shallowing of anterior chamber — may lead to angle-closure glaucoma

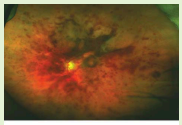

(© 2020 American Academy of Ophthalmology)

Hemiretinal vein occlusion

- congenital variation in central vein anatomy

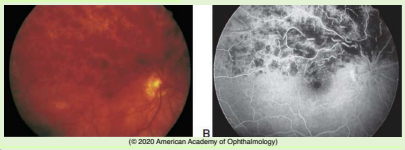

(© 2020 American Academy of Ophthalmology)

Complications

- iris neovascularization
  - in ≤ 60% of eyes with ischemic CRVO
  - 3-5 months after onset of symptoms
  - risk factors (CVOS)
    - poor visual acuity
    - large areas of retinal capillary nonperfusion
    - large areas of intraretinal blood
    - ERG did not add to risk factors!
  - treatment (CVOS)
    - scatter PRP
      - if ≥2 clock-hours of NVI on undilated gonioscopy (CVOS)
      - in clinical practice is performed at the first sign of NVI
    - intravitreal anti-VEGF agents
      - reduce NVI in short term
- vitreous hemorrhage
  - can happen in absence of neovascularization

Differential diagnosis

- hypercoagulable conditions
  - hyperhomocysteinemia
  - protein S deficiency
  - protein C deficiency
- hyperviscolsity retinopathy
  - dysproteinemia
    - bilateral
    - Waldenstrom macroglobulinemia
    - multiple myeloma
  - blood dyscrasias
    - polycythemia vera
  - diagnostic testing
    - CBC
    - serum protein electrophoresis
    - measurement of whole blood viscosity
- ocular ischemic syndrome
  - hemorrhages limited to deeper retinal layers
  - no vascular tortuosity
- vasculitis
  - sarcoidosis
  - systemic lupus erythematosus

evaluation & management

- examination
  - visual acuity
  - APD
  - IOP measurement
    - treat any elevation of IOP in affected or fellow eye
  - gonioscopy
    - CRVO can lead to transient shallowing of AC
    - check regularly for NVI
    - monitor every month x 6 months
- ancillary testing
  - visual field
  - fluorescein angiography
  - ERG
  - CRVO after age 50 years does not require elaborate systemic workup
- lab tests
  - > 50 years
    - check for common risk factors
  - < 50 years
    - check for hypercoagulable conditions/thrombophilia
      - hyperhomocysteinemia
      - protein S deficiency
      - protein C deficiency
    - especially if
      - bilateral CRVO
      - history of previous thrombosis
      - family history of thrombosis
- treatment of associated medical conditions
  - hypertension
  - hypercholesterolemia
  - diabetes
  - hyperhomocyteinemia
  - smoking
- patient should report worsening vision
  - non-ischemic CRVO can progress to ischemic CRVO
    - CVOS
      - 16% in 4 months
      - 34% in 36 months

treatment

- pharmacologic management
  - mainstay of treatment
- laser management
  - grid pattern photocoagulation for macular edema (CVOS)
    - not recommended
    - reduced angiographic evidence of macular edema
    - did not improve visual acuity
  - PRP (CVOS)
    - prophylactic PRP did not result in decrease in NVI
      - 20% still developed NVI
    - perform PRP at first sign of NVI
- pars plana vitrectomy
  - vitreous hemorrhage
    - endolaser for NVI
    - visual rehabilitation
- abandoned surgical procedures
  - radial optic neurotomy
    - radial relaxing incision of scleral ring
  - creation of laser anastomosis between retinal vein and choroidal circulation
  - retinal vein canulation with infusion of tissue plasminogen activator
- systemic anticoagulation
  - not recommended

Ophthalmology Mind Maps/Arman Mashayekhi, MD