

4.9.2. Lens (II): Degenerations

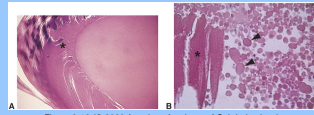
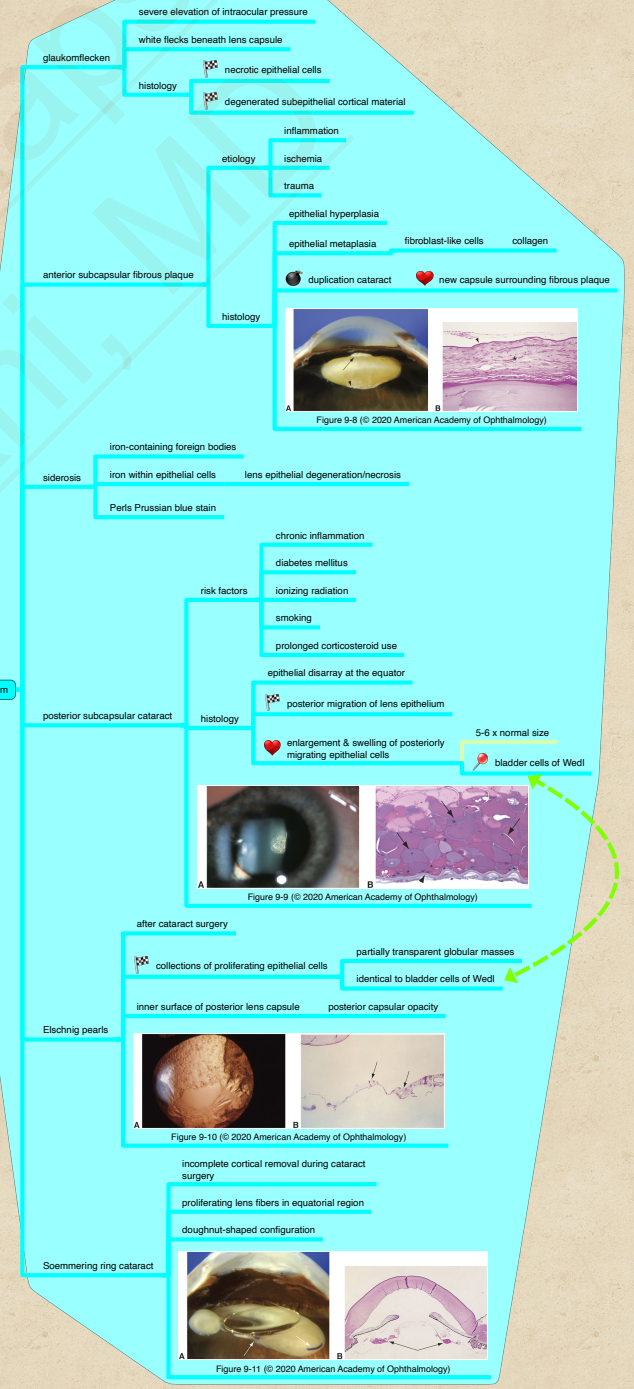
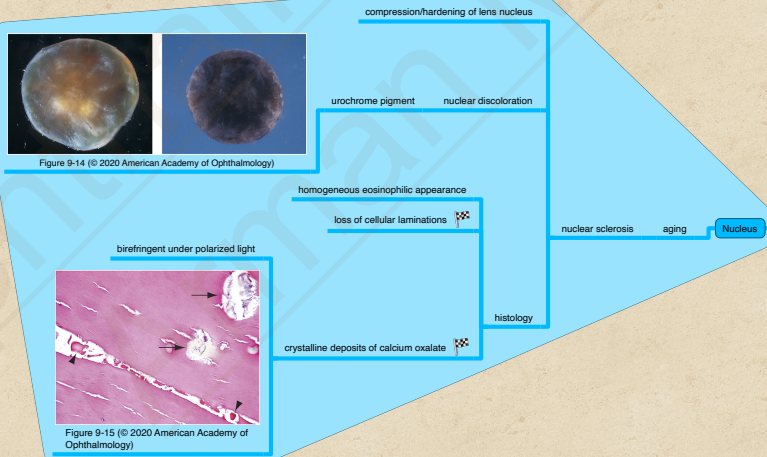
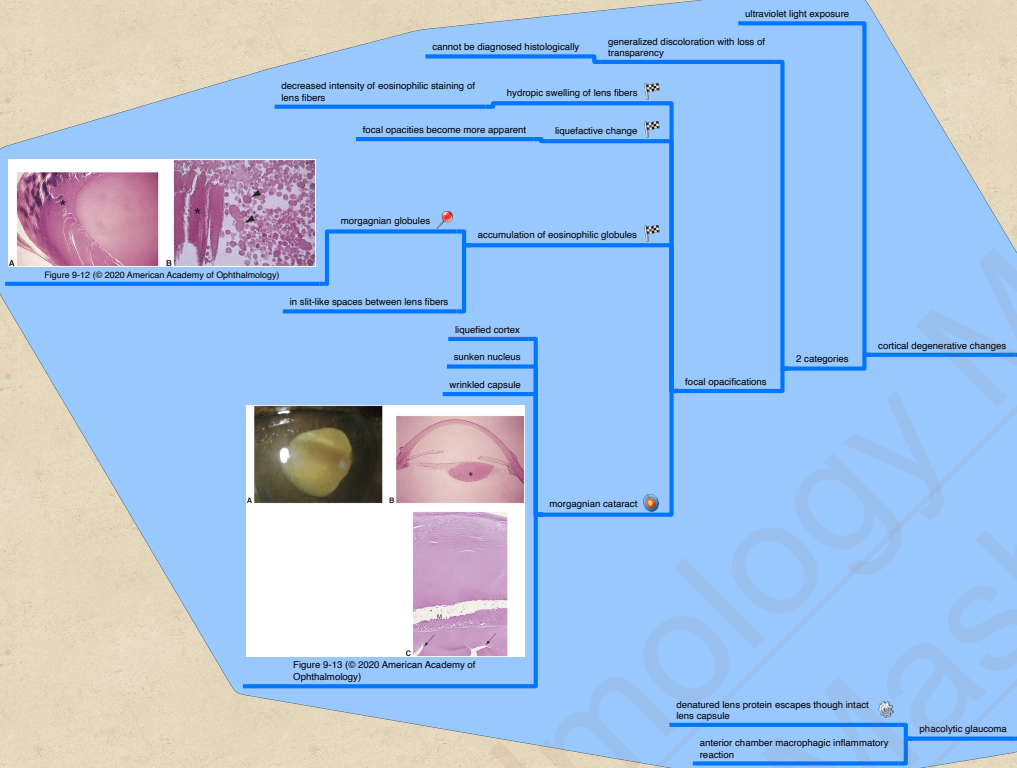
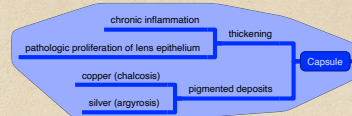


Figure 9-12 (© 2020 American Academy of Ophthalmology)

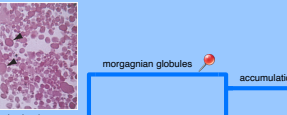

Figure 9-13 (© 2020 American Academy of Ophthalmology)

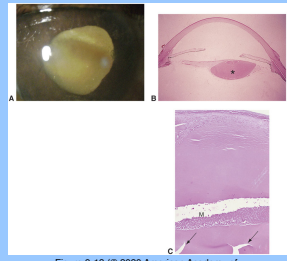


Figure 9-13 (© 2020 American Academy of Ophthalmology)

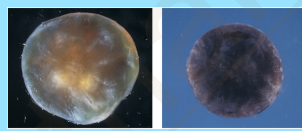


Figure 9-14 (© 2020 American Academy of Ophthalmology)

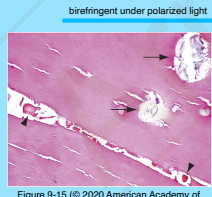


Figure 9-15 (© 2020 American Academy of Ophthalmology)

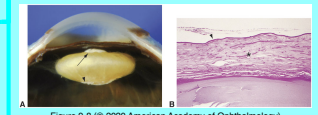

Figure 9-8 (© 2020 American Academy of Ophthalmology)

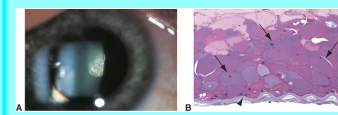


Figure 9-9 (© 2020 American Academy of Ophthalmology)

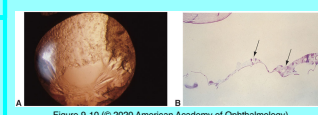


Figure 9-10 (© 2020 American Academy of Ophthalmology)

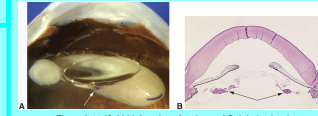


Figure 9-11 (© 2020 American Academy of Ophthalmology)