4.14.3. Orbit (III): Neoplasia (I)

- **Vascular tumors**
  - Lymphangioma
    - children
    - fluctuating proptosis
    - histology
      - diffusely infiltrating
      - unencapsulated
      - lymphatic vascular spaces
      - lymphoid aggregates
      - fibrotic interstitium
    - 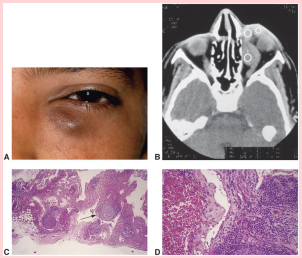
      Figure 14-9 (© 2020 American Academy of Ophthalmology)
  - Cavernous hemangioma
    - adults
    - histology
      - encapsulated
      - cavernous spaces
        - thick fibrosed walls
        - thrombosis
        - calcification
    - 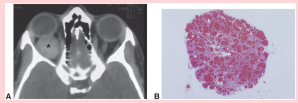
      Figure 14-10 (© 2020 American Academy of Ophthalmology)
  - Capillary hemangioma
    - children
    - histology
      - capillary-sized vessels
      - unencapsulated
      - more cellular
- **Soft tissue tumors**
  - histologic patterns
    - round cell
    - spindle cell
    - myxoid
    - epithelial
    - pericytomatous
    - pleomorphic
  - immunohistochemistry panel
    - CD34
    - CD68
    - CD99
    - S-100
    - vimentin
    - actin
    - desmin
  - malignant (sarcoma)
    - 2 groups
      - specific genetic alterations (simple karyotypes)/oncogenic mutations
        - FUS-DDIT3 in myxoid sarcoma
        - KIT mutation in GI stromal tumors
      - nonspecific genetic alterations (complex karyotypes)
- **Metastatic tumors**
  - secondary tumors
    - direct extension from adjacent structures
  - metastatic tumors
    - spread from a primary site
      - women — breast
      - men — prostate
      - children — neuroblastoma
- **Adipose tumors**
  - Lipoma
    - rare
    - encapsulated
    - lobular appearance
  - Liposarcoma
    - extremely rare
    - lipoblasts
    - recur before metastasizing
- **general**
  - types
    - primary
      - less common
        - lymphoma — 10%
        - cavernous hemangioma — 5%
    - secondary
      - ★ more common
      - from adjacent structures
      - metastatic disease
  - benign vs. malignant
    - benign — 60%
      - more common in children — 90%
      - cystic lesions — 50% of orbital lesions in childhood
    - malignant — 40%
      - more common in adults
- **Lacrimal sac neoplasia**
  - rare
  - difficult to get a representative biopsy with endoscopic procedures
  - dacryocystorhinostomy — 5% neoplasm rate — 2% unsuspected
- **Lymphoproliferative lesions**
  - general
    - clinical
      - proptosis
        - gradual
        - painless
    - systemic evaluation
      - physical examination
        - lymphadenopathy
          - lymph node biopsy preferred over orbital biopsy
      - CBC & differential
      - imaging of thorax & abdomen
      - +- bone marrow biopsy
        - paratrabecular lymphoid infiltrate
        - preferred to aspiration
    - treatment
      - radiation
      - communicate with pathologist in advance!
    - tissue processing
      - fresh (unfixed) tissue
        - preferred for
          - touch preperation
          - immunohistochemistry
          - flow cytometry
          - gene rearrangement
        - avoid long periods of exposure to air
        - wrap in saline-moistened gauze and transport on ice
        - handle gently
  - Reactive lymphoid hyperplasia
    - lymphocytes
      - well-differentiated
      - pleomorphic
    - follicles with germinal centers
      - tingible body macrophages
        - contain phagocytized apoptotic cellular debris/ condensed chromatin fragments
    - mitotic activity
    - vessels with endothelial activity
    - plasma cells
    - macrophages
    - eosinophils
  - Atypical lymphoid hyperplasia
    - ✘ lacks reactive germinal centers
    - admixture of
      - small mature-appearing lymphocytes
      - larger lymphoid cells of questionable maturity
  - Lymphoma
    - types
      - primary
      - systemic lymphoma (secondary)
        - 1-2% of systemic lymphoma are associated with orbital lymphoma
    - Hodgkin lymphoma exceedingly rare in orbit
      - multinucleated Reed-Sternberg cells
      - positive immunohistochemistry for
        - CD15
        - CD30
        - CD45
    - non-Hodgkin lymphoma
      - 1/2 of malignancies in orbit/ocular adnexa
      - immunohistochemistry
        - B cell
          - CD19
          - CD20
        - T cell
          - rare
          - CD3, CD4, CD5
      - 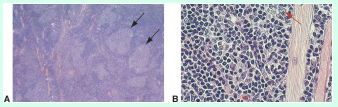
        Figure 14-8 (© 2020 American Academy of Ophthalmology)

Ophthalmology Mind Maps/Arman Mashayekhi, MD