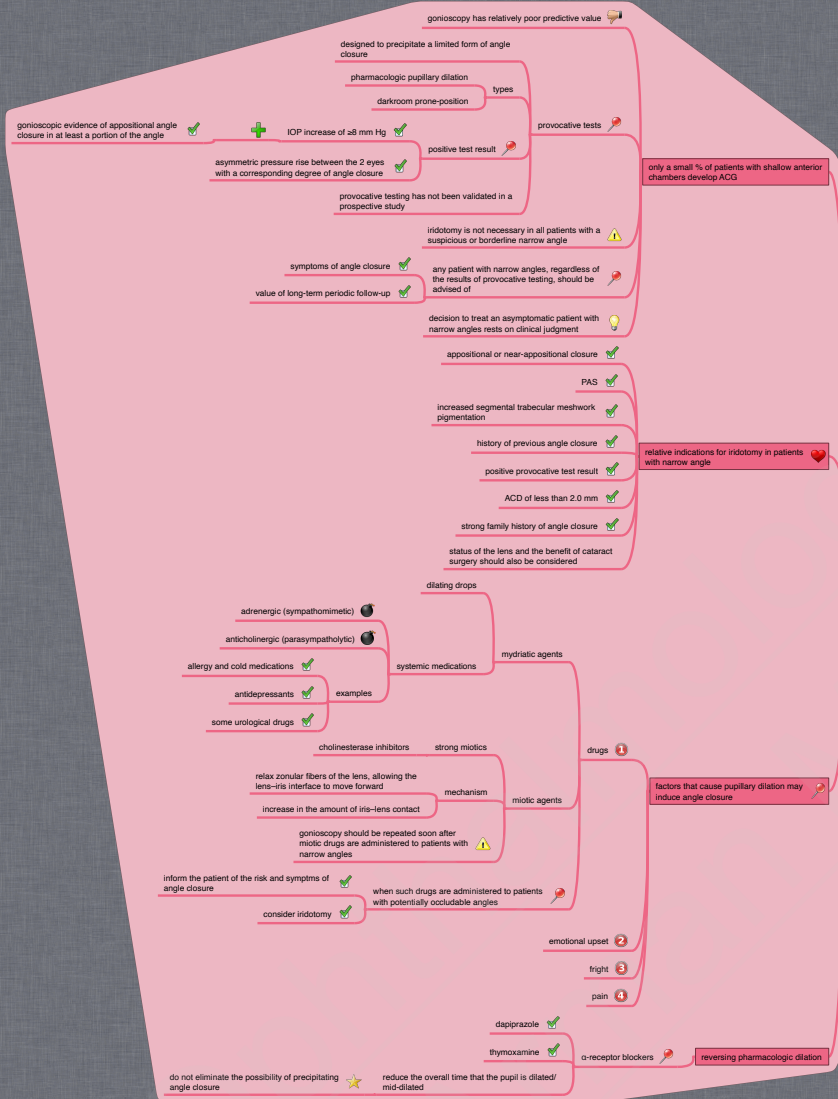
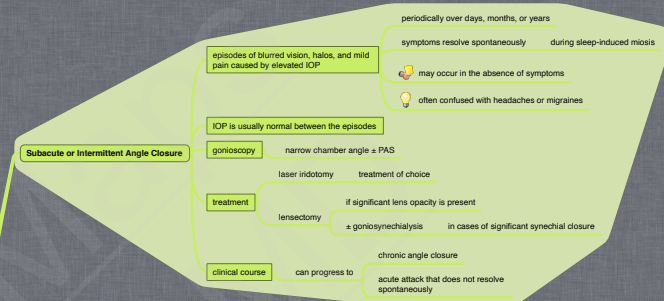


10.5.2. Angle-Closure Glaucoma (II): Primary Angle Closure (II)

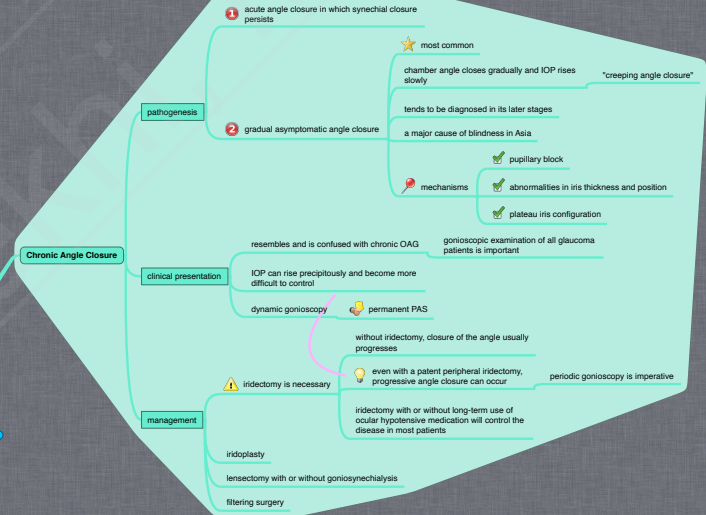
The Occludable/Narrow Anterior Chamber Angle



Subacute or Intermittent Angle Closure



Chronic Angle Closure



Plateau Iris

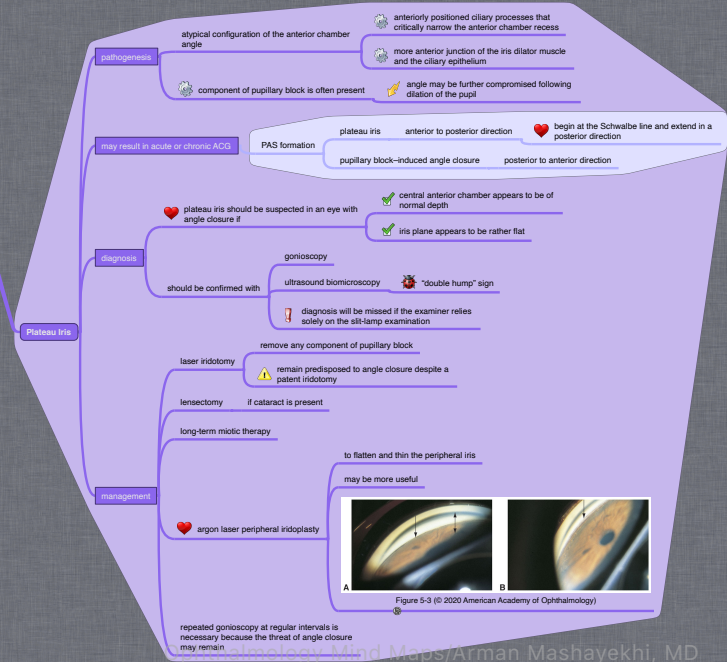


Figure 5-3 (© 2020 American Academy of Ophthalmology)