5.9.1. Nystagmus (I)

Introduction

- **definition**
  - nystagmus
    - rhythmic, to-and-fro eye movements that incorporate a slow phase
    - 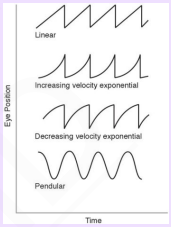

      Figure 9-1 (© 2020 American Academy of Ophthalmology)
  - **jerk nystagmus**
    - has 2 phases
      - (1) a slow-phase drift from the visual target
      - (2) a corrective saccade (fast phase) back to the target
    - direction of jerk nystagmus is reported as the direction of its fast-phase component
    - slow-phase component indicates the pathology
  - **pendular nystagmus**
    - back-and-forth slow-phase movements that occur without a fast phase
  - **saccadic intrusions/oscillations**
    - abnormal saccadic movements
      - adversely affect visual fixation
      - have no slow phase
  - **dissociated nystagmus**
    - amplitude of oscillations differs in each eye
  - **disconjugate/disjunctive nystagmus**
    - direction of oscillations differs between the 2 eyes
  - **oscillopsia**
    - sensation of environmental movement
    - acquired nystagmus
    - absent in children with congenital nystagmus
- **history**
  - associated neurologic symptoms
    - vertigo
    - ataxia
    - motor weakness
    - sensory weakness
  - family history of abnormal eye movements or strabismus
- **clinical presentation**
  - a few beats of nystagmus are normally present in the extremes of horizontal gaze (beyond 45°)
    - especially in older patients
    - should not be considered pathologic unless the nystagmus is
      - persistent
      - asymmetric (eg, present to the left but not the right)
      - accompanied by other features
  - nystagmus in primary position may degrade visual acuity
  - any abnormal eye movement in the cardinal positions should be examined
    - monocular or binocular
    - conjugate
      - the eyes behave similarly
    - horizontal, vertical, torsional, or mixed in pattern
    - continuous or induced by a particular eye position
    - characterized by slow phases only (ie, pendular nystagmus), fast-and-slow phases (ie, jerk nystagmus), or fast phases only (ie, saccadic intrusion)
    - reduced at a null point
      - field of gaze at which the nystagmus is minimal
  - amplitude of nystagmus often changes with gaze position
- **diagnostic workup**
  - illuminated Frenzel (high-magnification) goggles
    - block the patient's fixation and magnify abnormal eye movements
  - 20 D lens
  - slit lamp
  - direct ophthalmoscope
  - ocular motor recordings
    - objective and highly sensitive measure of eye movements
    - rarely needed in standard clinical practice
  - video recording

Gaze-Evoked Nystagmus

- **inability to maintain fixation in eccentric gaze**
  - eyes drift back to the midline
    - a corrective saccade is generated to reposition the eyes on the eccentric target
      - fast phase is always in the direction of gaze
- **Alexander's law**
  - nystagmus increases in intensity (amplitude and frequency) as the eyes are moved in the direction of the fast phase
- **pathogenesis**
  - dysfunction of the neural integrator
    - horizontal gaze
      - nucleus prepositus hypoglossi
      - medial vestibular nuclei
    - vertical gaze
      - interstitial nucleus of Cajal
      - flocculus and nodulus of the cerebellum also play a role in maintaining an eccentric position of gaze
    - neural control of eye movements
      - • nucleus prepositus hypoglossi: neural integrator for horizontal eye movements
      - • PPRF: saccadic generator for horizontal eye movements (pons)
      - • interstitial nucleus of Cajal: neural integrator for vertical and torsional eye movements
      - • riMLF: saccadic generator for vertical (and torsional) eye movements (midbrain)
- **a few beats of symmetric jerk nystagmus at the extremes of far horizontal gaze is physiologic**
  - no rebound nystagmus
  - no saccadic dysmetria
- **further evaluation is required if**
  - nystagmus is asymmetric
  - nystagmus is sustained
- **etiology**
  - metabolic/toxic (1)
    - ethanol
    - anticonvulsants
    - sedatives
    - hypnotics
  - ipsilateral lesion of the brainstem or cerebellum (2)
    - stroke
    - demyelination
    - tumor
  - end-organ disease (3)
    - extraocular myopathies
    - myasthenia
    - pattern similar to that observed with lesions of the central nervous system
- **Rebound Nystagmus**
  - after prolonged eccentric viewing
    - jerk nystagmus in the opposite direction after an attempted return to primary gaze
  - often a manifestation of cerebellar disease

Ophthalmology Mind Maps/Arman Mashayekhi, MD