Coats Disease & Parafoveal Retinal Telangiectasia

Parafoveal (Juxtafoveal) Retinal Telangiectasia

Clinical findings
- telangiectasia of the capillary bed
- focal retinal gliosis
- juxtafoveolar region of 1 or both eyes
- capillary incompetence and exudation
- refractile changes ("retinal crystals") — advanced cases

Histology
- structural abnormalities similar to those of diabetic microangiopathy — not a true telangiectasia
- deposits of excess basement membrane within the retinal capillaries

3 types

Type 1 — *aneurysmal telangiectasia*
- males
- unilateral
- congenital or acquired
- circinate type of exudate
- resembles macular variant of Coats disease — *Leber miliary aneurysm*

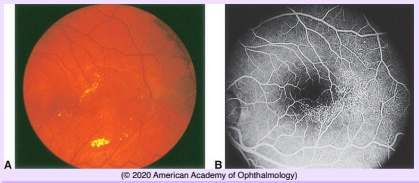

(© 2020 American Academy of Ophthalmology)

Type 2 — *perifoveal telangiectasia*
- bilateral
- no sex predilection
- retinal changes
  - thickening
  - loss of transparency with a grayish appearance
  - small telangiectatic vessels
  - cystic appearance of the fovea
  - temporal fovea
- chronic changes
  - intralesional retinal pigment epithelium (RPE) migration
  - choroidal neovascularization
- vision loss ranges from mild to severe
- 1/3 abnormal glucose tolerance test ☆
- right-angle retinal venules — dive at a right angle into deeper retinal layers

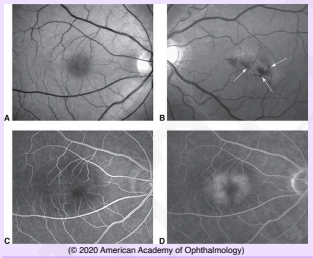

(© 2020 American Academy of Ophthalmology)

Type 3
- ***bilateral parafoveal telangiectasia with retinal capillary obliteration*** — progressive vision loss from perifoveal capillary occlusion

Imaging
- fluorescein angiography — leakage of telangiectatic vessels
- OCT
  - thinned central macular retina
  - inner lamellar oblong foveal cavitations — long axis is parallel to the retinal surface

Differential diagnosis
- branch retinal vein or venule obstruction
- diabetes mellitus
- radiation retinopathy
- cystoid macular edema (especially chronic)
- carotid artery disease

Treatment
- Photocoagulation
  - for type 1
  - Type 2 and type 3 eyes typically do not respond to photocoagulation ☆
- anti-VEGF drugs — limited success

Coats Disease

General
- male predominance (85%)
- only 1 eye is involved
- ✖ not hereditary — an associated gene has been identified on chromosome 4
- ✖ not associated with systemic disease

Pathogenesis
- abnormal vessels are incompetent — leakage of serum and other blood components

Clinical
- peripheral and macular capillary system may be involved
  - vascular dilatations (retinal telangiectasia)
  - ectatic arterioles
  - microaneurysms
  - venous dilations (phlebectasias)
  - fusiform capillary dilatations
- exudative retinal detachment
- lipid exudation — lipid may deposit in an otherwise angiographically normal macula
  - submacular lipogranuloma
  - subretinal fibrosis
- fluorescein angiography — retinal capillary nonperfusion
- posterior segment neovascularization is unusual — may simulate retinoblastoma
- ☆ severity and rate of progression greater in children < 4 years — massive exudative retinal detachment — retina apposed to the lens

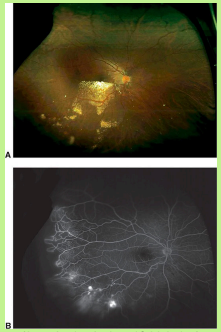

(© 2020 American Academy of Ophthalmology)

Differential Diagnosis
- dominant (familial) exudative vitreoretinopathy
- facioscapulohumeral muscular dystrophy
- retinopathy of prematurity (ROP)
- diabetic retinopathy
- BRVO
- juxtafoveal retinal telangiectasia
- radiation retinopathy

Treatment
- photocoagulation
- cryotherapy
- retinal reattachment surgery
- several treatments may be necessary

Ophthalmology Mind Maps/Arman Mashayekhi, MD