8.10.2. Corneal Dystrophies (II): Bowman Layer Dystrophies

See Table 10-1

Thiel-Behnke corneal dystrophy (TBCD)

- autosomal dominant
  - TGFBI
    - similar to Reis-Bucklers
  - 5q31
  - unknown gene
  - 10q24
- pathology
  - pathognomonic wavy, "saw-toothed" pattern
  - Bowman layer is replaced by fibrocellular material
  - thickening of epithelial layer
    - allows for ridges and furrows in underlying stroma
  - focal absences of the epithelial basement membrane
- electron microscopy
  - curly fibers (9–15 nm) distinguish this dystrophy from RBCD
  - immunopositive for the TGFBI protein keratoepithelin associated with the 5q31 genetic locus
- clinical presentation
  - onset is in the first or second decade of life
    - similar to Reis-Bucklers
  - symptoms
    - reduced vision
    - discomfort and pain
  - clinically distinguishing TBCD from RBCD is difficult
  - symmetric subepithelial reticular (honeycomb) opacities
    - initially spare the peripheral cornea
      - may progress to deep stromal layers and corneal periphery
      - similar to Reis-Bucklers
      - unlike granular dystrophy
    -
      Figure 10-7 (© 2020 American Academy of Ophthalmology)
  - recurrent erosions
    - erosions in TBCD are less frequent and less severe than those with RBCD
  - corneal opacification
- treatment
  - similar to that used in RBCD

Reis-Bücklers corneal dystrophy (RBCD)

- genetics
  - autosomal dominant
  - 5q31
  - gene TGFBI
- pathology
  - Bowman layer is disrupted or absent
    - replaced by a sheetlike connective tissue layer
    - granular Masson trichrome-red deposits
- electron microscopy
  - electron-dense, rod-shaped bodies
  - TGFBI protein keratoepithelin
  - electron microscopy is needed to histologically distinguish RBCD from Thiel-Behnke corneal dystrophy, which has curly fibers
- clinical presentation
  - appears in the first few years of life
  - confluent, irregular, and coarse geographic opacities with varying densities
    - mainly affects the Bowman layer
    - mostly centrally
      - with time, opacities extend to limbus and deeper stroma
      - unlike granular dystrophy
  - stromal scarring can lead to surface irregularity
  - 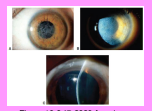
    Figure 10-6 (© 2020 American Academy of Ophthalmology)
- symptoms
  - begin in first or second decade of life
    - painful recurrent epithelial erosions
      - occur less often over time
      - usually more severe and frequent than those in Thiel-Behnke corneal dystrophy
  - decreased vision
    - anterior scarring with surface irregularity
    - anterior stromal edema
- treatment
  - treat recurrent erosions
  - technique
    - superficial keratectomy
    - LK
    - PTK
    - PK
  - recurrence in the graft is common

Ophthalmology Mind Maps/Arman Mashayekhi, MD