

## 7.10.6. Eyelid Neoplasms (III): Benign Melanocytic Lesions

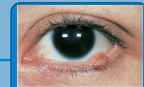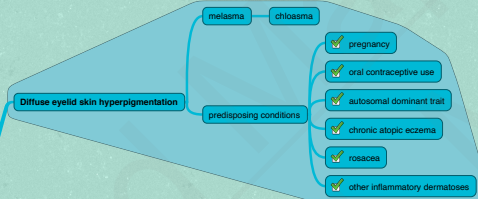
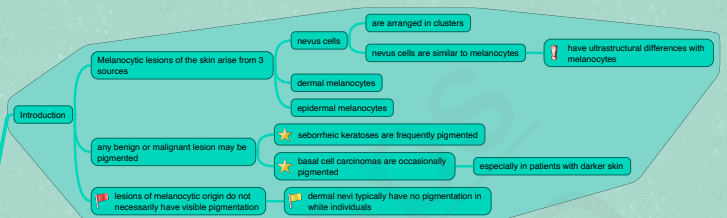


Figure 10-23 (© 2020 American Academy of Ophthalmology)

