4.2.2. Histologic Sequelae of Ocular Trauma

- **Fibrocellular proliferation**
  - Penetrating trauma
    - Hemorrhage
      - Sequelae
        - Hemoglobin spherulosis
        - Cholesterolosis
        - Siderosis bulbi
      - Hemosiderin at 72 hours
    - Tractional retinal detachment
    - Proliferative vitreoretinopathy
    - Hypotony & phthisis bulbi

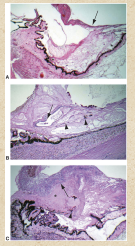
Figure 2-9 (© 2020 American Academy of Ophthalmology)

- **Bruch membrane/choroidal rupture**
  - Direct/Indirect trauma
  - Sequelae
    - Choroidal neovascularization
    - Granulation tissue proliferation
    - Focal post-traumatic choroidal granulomatous inflammation
      - After projectile injury
    - Chorioretinal rupture & necrosis
    - Sclopetaria

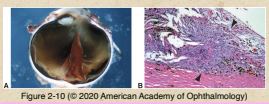
Figure 2-10 (© 2020 American Academy of Ophthalmology)

- **Phthisis bulbi**
  - Atrophia bulbia without shrinkage
    - Loss of nutrition
      - Cataract
      - Serous retinal detachment
      - Anterior/Posterior synechiae
        - High intraocular pressure
  - Atrophia bulbia with shrinkage
    - Ciliary body dysfunction
      - Low intraocular pressure
        - Small, squared-off eyeball
      - Corneal edema/scarring/vascularization
  - Phthisis bulbi
    - 16-19 mm eyeball
    - Disorganized intraocular structures
    - Retinal pigment epithelial proliferation/Drusen
    - Osseous metaplasia of retinal pigment epithelium
    - Scleral thickening
    - Calcification
      - Bowman layer
      - Lens
      - Retina
      - Drusen

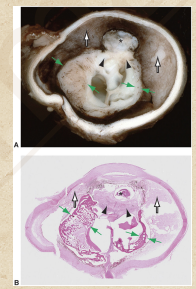
Figure 2-11 (© 2020 American Academy of Ophthalmology)

- **Rupture of the Descemet membrane**
  - keratoconus

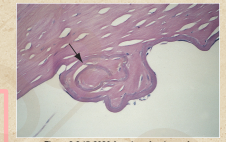
Figure 2-3 (© 2020 American Academy of Ophthalmology)

  - forceps trauma

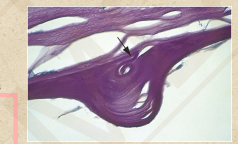
Figure 2-4 (© 2020 American Academy of Ophthalmology)

- **Cyclodialysis**
  - Disinsertion of longitudinal muscle of ciliary body from scleral spur
  - Hypotony
    - Increased aqueous drainage
    - Decreased aqueous production

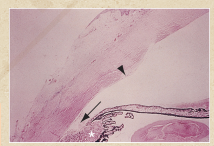
Figure 2-5 (© 2020 American Academy of Ophthalmology)

- **Anterior chamber angle recession**
  - Tear between longitudinal and circular muscles of ciliary body
  - Posterior displacement of the iris root
  - Concurrent damage to the trabecular meshwork

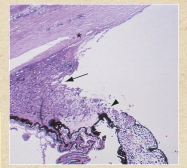
Figure 2-6 (© 2020 American Academy of Ophthalmology)

- **Attachments between uvea and sclera**
  - 1. Scleral spur
  - 2. Ostia of vortex veins
  - 3. Peripapillary area
  - Borders of a dome-shaped choroidal hemorrhage are defined by the position of vortex veins and scleral spur

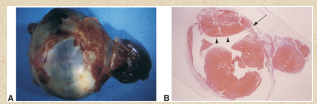
Figure 2-7 (© 2020 American Academy of Ophthalmology)

- **Iridodialysis**
  - Tear at iris base

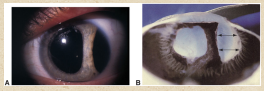
Figure 2-8 (© 2020 American Academy of Ophthalmology)

- **Iris sphincter rupture**
  - Notch at pupillary margin
- **Vossius ring**
  - Iris pigment epithelial damage
  - Ring of pigment on anterior lens surface
- **Lens damage**
  - Cataract
    - Lens capsule thinnest at posterior pole
  - Anterior lenticular fibrous plaque
  - Zonular rupture
    - Subluxation/Dislocation of lens
    - Vitreous prolapse into anterior chamber
- **Commotio retinae**
  - Blunt trauma
    - Disruption in architecture of photoreceptors
- **Retinal dialysis**
  - Blunt trauma
    - Tear at:
      - Ora
      - Posterior margin of vitreous base
      - Circumferential location
        - Inferotemporal
        - Superonasal

Ophthalmology Mind Maps/Arman Mashayekhi, MD