4.11.2. Retina & Retinal pigment Epithelium (II)

Peripheral retinal degenerations

- Peripheral cystoid degeneration
  - Typical peripheral cystoid degeneration
    - all eyes after age 20 years
    - outer plexiform layer
    - causes typical degenerative retinoschisis
      - inferotemporal
    -
      Figure 11-8 (© 2020 American Academy of Ophthalmology)
  - Reticular peripheral cystoid degeneration
    - less common
    - nerve fiber layer
    - posterior to areas of typical peripheral cystoid degeneration
    - causes reticular degenerative retinoschisis
- Lattice degeneration
  - demographics
    - 10% of general population
    - 40% of rhegmatogenous retinal detachments
    - +- familial
  - histology
    - ILM discontinuity
    - variable inner retinal atrophy
    - overlying pocket of liquefied vitreous
    - sclerosis of retinal vessels
      - patent
    - condensation & adherence of vitreous at margins of lattice
  - complications
    - atrophic holes
      - in the center of lattice
      - rare cause of RD
    - retinal tear
      - at margin of lattice
      - can cause RD
    - radial perivascular lattice degeneration
      - more posteriorly
      - along retinal vessels
    - 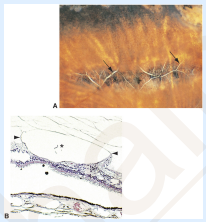
      Figure 11-11 (© 2020 American Academy of Ophthalmology)
- Paving-stone (cobblestone) degeneration
  - clinical
    - peripheral retina
    - well-demarcated
    - flat
    - pale
  - histology
    - RPE atrophy
    - outer retinal atrophy
      - lattice degeneration causes inner retinal atrophy
    - adherence of inner nuclear layer to Bruch membrane
  - 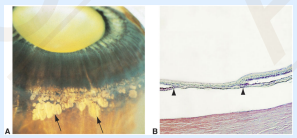
    Figure 11-12 (© 2020 American Academy of Ophthalmology)

Congenital Anomalies

- Albinism
  - true albinism
    - oculocutaneous
      - autosomal recessive
      - decreased melanin in melanosomes
    - ocular
      - X-linked recessive
      - decreased # of melanosomes
      - mild cutaneous albinism
    - 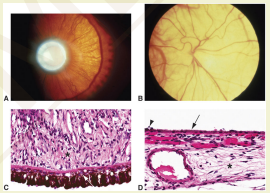
      Figure 11-3 (© 2020 American Academy of Ophthalmology)
- Myelinated nerve fibers
  - oligodendroglial cells
  - usually contiguous with the optic nerve head
  - scotoma if large
  - associated with
    - myopia
    - amblyopia
    - strabismus
    - nystagmus
- Vascular anomalies
  - Coats disease
    - subretinal space
      - foamy macrophages
      - cholesterol crystals
    - 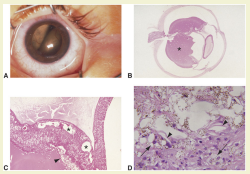
      Figure 11-4 (© 2020 American Academy of Ophthalmology)
- Congenital hypertrophy of RPE
  - clinical
    - flat
    - dark black
    - few-10 mm
    - lacunae
  - histology
    - enlarged (hypertrophic) RPE cells
    - melanin granules
      - densely packed
      - large
      - spherical
    - rare adenoma/adenocarcinoma of RPE
    - 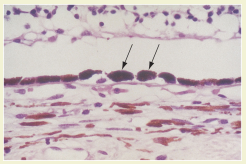
      Figure 11-5 (© 2020 American Academy of Ophthalmology)
  - differential diagnosis
    - familial adenomatous polyposis (Gardner syndrome)
      - hamartoma
      - hyperplasia of RPE

Ophthalmology Mind Maps
Arman Mashayekhi, MD