Developmental Abnormalities of Vitreous (I)

Persistent Fetal Vasculature

General

- failure of primary vascular vitreous to regress
- congenital
- 90% unilateral
- bilateral cases may be associated with systemic or neurologic abnormalities
- can be asymmetric and bilateral
- genetics
  - most common
  - sporadic
  - ATOH7 gene
  - autosomal recessive
  - autosomal dominant
- no associated systemic findings

Anterior persistent fetal vasculature

Clinical Findings

- microphthalmos
- shallow anterior chambe
- leukocoria
- densest centrally
- may contain cartilage and fibrovascular tissue
- white vascularized fibrous membrane or mass behind lens

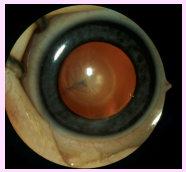

(© 2020 American Academy of Ophthalmology)

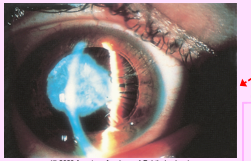

(© 2020 American Academy of Ophthalmology)

- elongated ciliary processes
- ciliary body detachment
- most common cause of a unilateral cataract
- cataract
- swollen lens with secondary angle-closure glaucoma
- dehiscence of posterior lens capsule
- incomplete development of chamber angle
- glaucoma
- prominent radial iris vessels

Natural course

- blindness in most advanced cases

Treatment

- to prevent angle-closure glaucoma
- secondary cataract is common
- lensectomy and removal of fibrovascular retrolental membrane
- sensory and refractive amblyopia

Differential diagnosis

- retinoblastoma
  - not obvious at birth
  - more often bilateral
  - almost never associated with microphthalmos or cataract
  - PFV is anterior in eye at birth
  - does not appear in anterior fundus until well after birth
- imaging shows calcification
  - echography
  - x-ray techniques

Posterior persistent fetal vasculature

Clinical Findings

- ± with anterior PFV
- isolated posterior PFV
  - ± microphthalmia
  - normal anterior chamber
  - no retrolental membrane
  - lens is clear
  - persistent hyaloid artery
  - stalk of tissue from optic disc

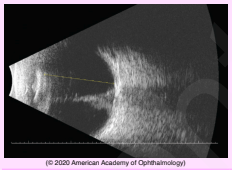

(© 2020 American Academy of Ophthalmology)

  - courses toward retrolental region
  - extends anteriorly from the optic nerve head
  - retinal fold
    - inferior quadrant
    - fans out circumferentially toward anterior retina
  - vitreous hemorrhage
  - congenital retinal nonattachment
  - optic nerve dysmorphis

Differential Diagnosis

- retinopathy of prematurity
- familial exudative vitreoretinopathy
- ocular toxocariasis
- retinoblastoma

Treatment

- lensectomy and vitrectomy
- formed vision in ≈ 70%

Tunica Vasculosa Lentis

- not visually significant
- Mittendorf dot
  - small, dense, white round plaque attached to the posterior lens capsule
  - nasal and inferior to lens posterior pole
- Bergmeister papilla
  - fibroglial tuft of tissue extending into the vitreous at the margin of optic nerve head
- persistent hyaloid artery
  - entire hyaloid artery may persist from optic nerve head to lens

Prepapillary Vascular Loops

- normal retinal vessels grow into Bergmeister papilla before returning to retina
  - <5 mm
  - 95% arterial
  - supply one or more quadrants of the retina
- complications
  - branch retinal artery obstruction
  - vitreous hemorrhage
  - amaurosis fugax

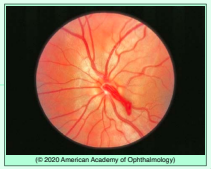

(© 2020 American Academy of Ophthalmology)

Ophthalmology Mind Maps/Arman Mashayekhi, MD