9.6.5. Chronic Anterior Uveitis (II): Juvenile Idiopathic Arthritis

- **epidemiology**
  - most common systemic disorder associated with anterior uveitis in the pediatric age group
- **definition**
  - arthritis < age 16 years
  - lasting ≥ 6 weeks
- **3 types**
  - oligoarticular onset
    - pauciarticular onset
      - 40%–50% of JIA
      - 80%–90% of JIA-associated uveitis
      - ≤ 4 joints during the first 6 months of disease
        - patients may have no joint symptoms
      - type 1
        - girls < 5 years
        - (+) antinuclear antibody (ANA)
        - chronic anterior uveitis occurs in ≤ 25%
      - type 2
        - older boys
        - (+) HLA-B27
          - 75%
          - many develop evidence of seronegative spondyloarthropathy
        - acute and recurrent uveitis (rather than chronic uveitis)
  - systemic onset (Still disease)
    - < 5 years
    - 10%–15% of JIA
    - fever, rash, lymphadenopathy, and hepatosplenomegaly
    - joint involvement may be minimal or absent initially
    - ocular involvement is rare
      - fewer than 6% of patients
  - polyarticular onset
    - > 4 joints in the first 6 months of the disease
    - 40% of JIA
    - ≈10% of JIA-associated anterior uveitis
      - rheumatoid factor (-) patients
      - rheumatoid factor (+) patients may not develop uveitis
- **uveitis**
  - average age of onset is 6 years
  - within 5–7 years of onset of joint disease
    - may occur as long as 28 years after development of arthritis
    - little or no correlation between ocular and joint inflammation
  - risk factors for the development of chronic uveitis
    - oligoarticular onset
    - female
    - (+) ANA
    - most patients test negative for rheumatoid factor
  - symptoms
    - eye is frequently white
    - mild to moderate pain
    - photophobia
    - blurring
    - some patients are asymptomatic
      - found incidentally during routine school physical examination
  - signs of inflammation include
    - fine KPs
    - band keratopathy

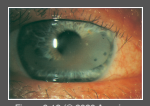

Figure 6-12 (© 2020 American Academy of Ophthalmology)

    - flare and cells
    - posterior synechiae
    - cataract

Figure 6-11 (© 2020 American Academy of Ophthalmology)

- **prognosis**
  - patients suspected of JIA should undergo
    - ANA testing
    - evaluation by a pediatric rheumatologist
      - joint disease may be minimal or absent at the time the uveitis is diagnosed!
  - differential diagnosis
    - TINU
    - Fuchs heterochromic uveitis
    - sarcoidosis
    - Behçet disease
    - seronegative spondyloarthropathies
    - herpetic uveitis
    - Lyme disease
  - profound silent ocular damage can occur
  - long-term prognosis depends on the extent of structural complications at first diagnosis
  - complications
    - band keratopathy
    - cataract
    - glaucoma
    - macular edema
    - chronic hypotony
      - phthisis
  - American Academy of Pediatrics recommendations for screening patients with JIA for uveitis
    - regular slit-lamp examinations specially necessary if
      - oligoarticular disease
      - ANA (+)
    - See Table 6-1
- **treatment**
  - goal of treatment is to eliminate active inflammation (anterior chamber cells)
    - even low-grade inflammation, if present for a prolonged period, can result in ocular morbidity
  - initial treatment
    - topical corticosteroids
  - more severe cases
    - systemic corticosteroids/IMT
  - corticosteroid-induced complications are common
    - growth retardation
    - cataracts
      - long-term use of topical corticosteroids at doses ≥3 times daily can increase the risk of cataract formation
        - systemic IMT should be considered for such cases
    - glaucoma
  - short-acting mydriatic drugs
    - in patients with chronic flare to prevent posterior synechiae formation
  - systemic NSAIDs
    - permit a lower dose of corticosteroids
  - low-dose methotrexate (weekly)
    - can effectively control the uveitis
    - well tolerated
    - can spare patients the complications of long-term corticosteroid use
  - TNF inhibitors and other biologic agents
  - cataract surgery in patients with JIA
    - high complication rate due to difficulty in controlling the more aggressive inflammatory response
    - use of IOLs remains controversial
      - aphakic children may develop amblyopia
    - lensectomy/vitrectomy via the pars plana
    - band keratopathy should be treated before cataract surgery
      - chelation EDTA
  - guidelines for cataract surgery with IOL implants in patients with JIA
    - intraocular inflammation must be well controlled with corticosteroids/systemic IMT for ≥3 months before surgery
      - IMT must be used preoperatively and postoperatively, not just perioperatively
      - must not require frequent instillation of topical corticosteroids
    - only acrylic IOL should be implanted
    - any inflammation after cataract surgery must be aggressively treated
    - patients must be strongly advised about the need for careful, regular, lifelong follow-up
    - low threshold for IOL explantation in patients who have persistent postoperative inflammation and recurrent cyclitic membranes.
  - glaucoma
    - should be treated with medical therapy initially
    - surgical intervention is often necessary in severe cases
    - standard filtering procedures are usually unsuccessful
      - antifibrotic drugs
      - aqueous drainage

Ophthalmology Mind Maps/Arman Mashayekhi, MD