5.14.10. Systemic Conditions (X): Cerebrovascular Disorders (II): Cerebral Aneurysms

Introduction

- demographics
  - 5% of the population
  - rarely become symptomatic <20 years
  - ± familial occurrence
- predisposing conditions
  - commonly associated with hypertension
  - arteriovenous malformations
  - coarctation of the aorta
  - polycystic kidney disease
  - connective tissue diseases
    - fibromuscular dysplasia
    - Marfan syndrome
    - Ehlers-Danlos syndrome
  - tobacco use
- saccular/"berry" aneurysm
  - most common type
  - at arterial bifurcations
  - locations
    - supratentorial — 90%
    - infratentorial — 10%
  - size
    - aneurysms >10 mm are most likely to rupture
    - "giant aneurysms" — ≥25 mm
- aneurysms arising from the internal carotid artery and basilar artery may produce neuro-ophthalmic manifestations
- high morbidity and mortality result from aneurysm rupture
  - early detection and surgical intervention can be life-saving

Clinical presentation

- unruptured aneurysms
  - progressive neurologic dysfunction
    - particularly giant aneurysms
    - ophthalmic artery aneurysm
      - progressive unilateral optic neuropathy
      - ipsilateral periocular pain
    - anterior communicating artery aneurysm
      - optic chiasm or optic tract compression
    - aneurysm at the junction of the internal carotid and posterior communicating arteries
      - ipsilateral third nerve palsy
        - complete third nerve palsy with pupil involvement or partial third nerve palsy ± pupil involvement should raise suspicion of an aneurysm and prompt immediate neuroimaging
    - intracavernous carotid artery aneurysm
      - fusiform enlargement (dolichoectasia)
        - not berry type
      - cavernous sinus syndrome
        - CN III, IV, VI and ophthalmic branch of CN V
          - singly or in combination
      - typically do not rupture but cause progressive neurologic dysfunction
      - often produce facial pain
        - consider in the differential diagnosis of painful ophthalmoplegia

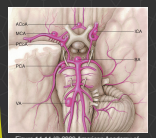

Figure 14-14 (© 2020 American Academy of Ophthalmology)

  - pain is not a helpful symptom
    - may be absent with unruptured aneurysms
    - may occur with cranial nerve palsies from microvascular ischemia
  - other neurologic findings
    - TIA
    - cerebral infarction
    - seizures
    - may be caused by flow phenomena or distal embolization
- ruptured aneurysm
  - neurosurgical emergency
  - subarachnoid or intraparenchymal hemorrhage
  - a "sentinel bleed" before the major rupture
  - headache
    - "the worst of my life"
    - localized or generalized
  - nausea, vomiting
  - neck stiffness
    - meningeal irritation from subarachnoid blood
  - fever
    - rare
  - elevated intracranial pressure
    - papilledema
    - sixth nerve palsies
  - altered mental status
    - disoriented, lethargic, or comatose
    - poor prognostic sign
  - ocular hemorrhage
    - may accompany subarachnoid hemorrhage
    - location
      - intraretinal
      - preretinal
        - subhyaloid
      - vitreous
      - subconjunctival
      - orbital
      - optic nerve sheath
    - Terson syndrome
      - subarachnoid hemorrhage + ocular hemorrhage

Figure 14-15 (© 2020 American Academy of Ophthalmology)

Diagnosis

- suspected aneurysm requires urgent neuroradiologic imaging
  - consult the neuroradiologist !
- 4-vessel study of both carotid and vertebral arteries is imperative
  - 10% of patients have multiple aneurysms !
- CTA
  - imaging modality of choice
- MRA
  - shows aneurysms ≥3 mm
- MRI
  - shows most aneurysms >5 mm
- conventional cerebral arteriography
  - high level of suspicion for aneurysm + negative finding on MRA or CTA
- CT scan
  - immediately after aneurysm rupture to detect the presence of intraparenchymal and subarachnoid blood
  - suspected subarachnoid hemorrhage + negative CT finding
    - CTA
    - lumbar puncture
      - should not be attempted in the presence of midline shift or evidence of cerebral (uncal) herniation
  - enhanced CT scan can show large aneurysms
    - not an acceptable screening test for unruptured aneurysms !

Figure 14-16 (© 2020 American Academy of Ophthalmology)

- to screen for unruptured aneurysms
  - less expensive and associated with lower morbidity than conventional angiography

Prognosis

- risk of rupture is related to size
  - <10 mm — <0.05% per year
  - ≥25 mm — 6% rupture in the first year
- once an aneurysm has ruptured, morbidity and mortality are high
  - 30% die at the time of rupture
  - untreated, another 33% die within 6 months
  - 15% more die within 10 years
  - many of those who survive suffer severe neurologic deficits
- references

Treatment

- treatment of symptomatic aneurysms before rupture is ideal
- supportive treatment to stabilize the patient
  - lower intracranial pressure
    - mannitol
      - hyperventilation
  - treatment of cerebral vasospasm
    - calcium channel blockers
    - blood volume expansion
    - control of blood pressure
- definitive treatment
  - surgical clipping of the aneurysm
  - intravascular techniques
    - coil embolization
    - stent placement
    - are replacing clipping as the preferred treatment
  - wrapping of the aneurysm wall
    - when aneurysm clipping is technically impossible
  - ligation of the feeding artery or carotid artery
    - when aneurysm clipping is technically impossible

Ophthalmology Mind Maps/Arman Mashayekhi, MD