11.3.2. Developmental Defects (I)

Microspherophakia

- faulty development of secondary lens fibers
- clinical presentation
  - small spherical lens
    - 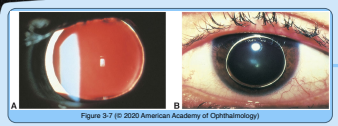
      Figure 3-7 (© 2020 American Academy of Ophthalmology)
  - high myopia
  - secondary angle-closure glaucoma
    - miotics aggravate this condition
    - cycloplegics are the medical treatment of choice
    - laser iridotomy
- associated syndromes
  - Weill-Marchesani syndrome
    - most common associated syndrome
    - autosomal recessive
    - small stature
    - short and stubby fingers
    - broad hands with reduced joint mobility
  - Marfan syndrome
  - Peters anomaly
  - Alport syndrome
  - Lowe syndrome
    - oculocerebrorenal syndrome of Lowe
      - x-linked
      - systemic acidosis
      - renal rickets
      - hypotonia
      - congenital cataract
        - focal, internally directed excrescences of lens capsule
      - microspherophakia
  - congenital rubella
  - isolated

Lenticonus and Lentiglobus

- lenticonus
  - anterior lenticonus
    - localized, cone-shaped deformation of the lens surface
    - often bilateral
    - may be associated with Alport syndrome
      - **Alport syndrome**
        - X-linked > AR > AD
        - disease of basement membranes
          - collagen type IV
        - extraocular presentation
          - progressive renal failure
            - late in the course of the disease
              - hypertension
              - kidney failure
          - hematuria
            - begins in childhood
          - sensori-neural deafness
        - ocular presentation
          - anterior lenticonus or anterior subcapsular cataract
          - posterior polymorphous dystrophy
          - fleck retinopathy
  - posterior lenticonus
    - more common
    - usually unilateral
- lentiglobus
  - localized spherical deformation of the lens surface
  - posterior lentiglobus is more common than anterior lentiglobus
    - often associated with posterior pole opacities
- retinoscopy
  - distorted and myopic reflex in both lenticonus and lentiglobus
- retroillumination
  - "oil droplet" reflex
    - 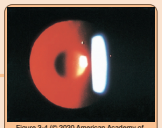
      Figure 3-4 (© 2020 American Academy of Ophthalmology)
- posterior bulging may progress
  - worsening myopia
  - opacification of the defect
  - +- opacification of surrounding cortical lamellae

Ophthalmology Mind Maps
Arman Mashayekhi, MD