7.12.2. Lacrimal System: Congenital Lacrimal Drainage Obstruction (I)

Dacryocystocele

- pathogenesis
  - congenital NLDO
    - functional block above lacrimal sac
      - +
  - amniotic fluid or mucus (secreted by lacrimal sac goblet cells) is trapped in tear sac
    - mucoceles
    - amniotocele
- within lacrimal sac
  - present at birth or within 1-4 weeks
  - inferior to medial canthal tendon
    - congenital swelling above the medial canthal tendon suggests alternate etiologies
      - meningoencephalocele
      - dermoid cyst
      - CT or MRI
  - management
    - conservative
      - prophylactic topical antibiotics
      - massage
      - initially sterile
    - probing of the lacrimal drainage system
      - indications
        - no response in 1–2 weeks
        - infection develops
- within nasal cavity
  - can be observed during nasal examination
  - at the level of occluded valve of Hasner
    - under the inferior turbinate
  - treatment
    - excision or marsupialization of duct
      - urgent treatment may be needed if the condition is bilateral and causes airway obstruction

Figure 13-8 (© 2020 American Academy of Ophthalmology)

Punctal/canalicular agenesis and dysgenesis

- punctal hypoplasia/dysgenesis
  - more common
- punctal aplasia/agenesis
  - truly absent punctum
    - determine canalicular status
      - canalicular system & nasolacrimal sac/duct are patent
        - intubation
      - complete absence of the puncta and the canalicular system
        - conjunctivodacryocystorhinostomy (CDCR) with Jones tube
      - symptomatic patients with a single punctum may require surgery to relieve NLDO rather than canalicular obstruction
      - technique
        - cut down medial to expected punctum location to identify canaliculus
        - retrograde probing through an open lacrimal sac with direct visualization of common canalicular opening
  - magnification may reveal intact punctum with thin overlying membrane
    - can usually be opened with a sharp probe
    - a temporary intubation or placement of silicone plug

Developmental abnormalities

- Lacrimal Secretory System
  - hypoplasia and agenesis of the lacrimal gland
    - associations
      - isolated
      - with congenital abnormalities of salivary glands
    - genetics
      - sporadic
        - most common
      - autosomal dominant
  - lacrimal gland prolapse
    - with craniosynostosis syndromes
  - ectopic lacrimal gland tissue
    - within the orbit and eyelids
  - aberrant ductule
    - "lacrimal gland fistula"
    - exits externally through the lateral eyelid several millimeters above the eyelash line
    - usually accompanied by adjacent cluster of eyelashes
    - simple excision
- Lacrimal Drainage System
  - Duplication
    - multiple puncta/canaliculi
    - types
      - extra opening on eyelid margin
        - asymptomatic

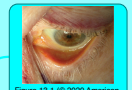

Figure 13-1 (© 2020 American Academy of Ophthalmology)

      - extra opening through skin
        - "congenital lacrimal–cutaneous fistula"
        - infranasal to the medial canthus
        - ± associated with tears that appear on skin
        - ≈1/3 have NLDO
          - chronic mucoid discharge
        - treatment
          - direct surgical excision of epithelium-lined fistulous tract with direct suture closure
          - silicone intubation or dacryocystorhinostomy
            - for underlying NLDO and chronic dacryocystitis

Figure 13-2 (© 2020 American Academy of Ophthalmology)

  - Aplasia and hypoplasia
  - Lacrimal drainage obstruction

Evaluation

- history
  - tearing or mucopurulent discharge
    - beginning shortly after birth
      - constant tearing with minimal mucopurulence
        - blockage of the upper system (puncta, canaliculi, and common canaliculus)
      - constant tearing with frequent mucopurulence and matting of the eyelashes
        - complete obstruction of the NLD
      - intermittent tearing with mucopurulence
        - intermittent obstruction of the NLD
- examination
  - inspection of the eyelid margins
    - puncta
    - extrinsic causes of reflex hypersecretion
      - ocular surface irritation
      - infectious conjunctivitis
      - epiblepharon
      - trichiasis
      - congenital glaucoma
  - inspection of the medial canthal region
    - distended lacrimal sac
      - below the tendon
    - encephalocele
      - above the tendon
    - inflammation
  - application of digital pressure over the tear sac
    - if mucoid reflux is present, complete obstruction at the level of the NLD becomes the working diagnosis

Ophthalmology Mind Maps/Arman Mashayekhi, MD