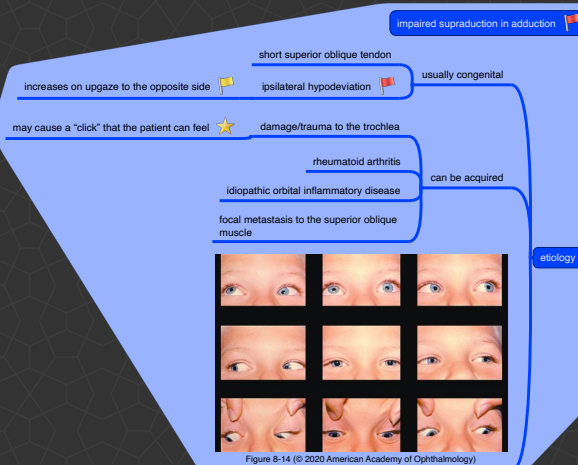


5.8.8. Diplopia (VIII): Infranuclear Causes of Diplopia (V)

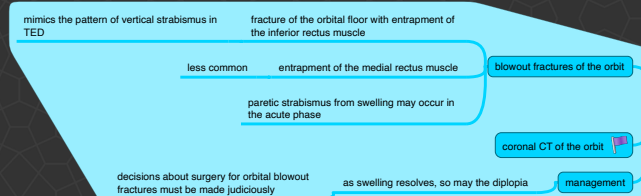
Brown Syndrome 😊

etiology

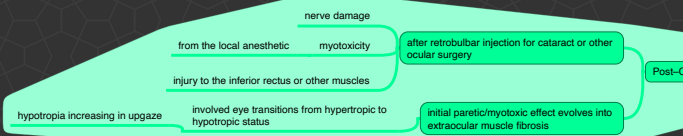


Posttraumatic Restriction

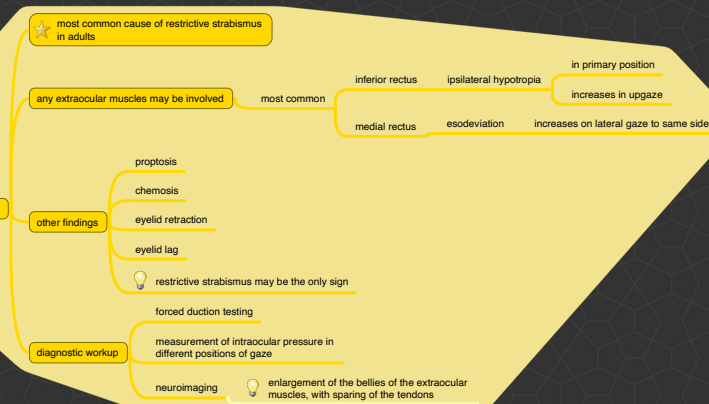
coronal CT of the orbit



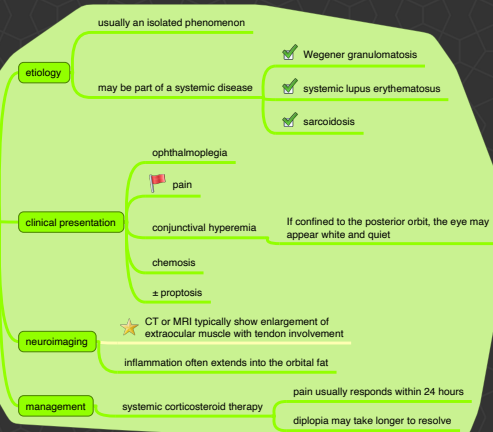
Post-Cataract Extraction Restriction



Thyroid Eye Disease (TED)



Orbital Myositis



Neoplastic Involvement

