7.10.9. Eyelid Neoplasms (VI)

Merkel cell carcinoma

- dendritic (neuroendocrine) skin cells
  - role in mediating sense of touch
  - can give rise to malignant neoplasms
    - 10% occur in the eyelid and periocular area
- clinical presentation
  - painless, erythematous nodules
  - overlying telangiectatic blood vessels
  - can mimic other malignant lesions
    - diagnosis can be difficult
- 1/3 of tumors recur after excision
- estimated 5-year survival rate
  - 50%
- treatment
  - should be aggressive
  - wide surgical resection
  - ±postoperative radiation and/or chemotherapy

Kaposi sarcoma

- rare
- manifestation of AIDS
- chronic reddish dermal mass

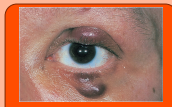

Figure 10-32 (© 2020 American Academy of Ophthalmology)

- conjunctival lesions can be mistaken for foreign-body granuloma or cavernous hemangioma
- composed of spindle cells of probable endothelial origin
- treatment
  - cryotherapy
  - excision
  - radiation
  - intralesional chemotherapeutic agents
  - may regress with adequate antiviral treatment of the HIV infection

Squamous cell carcinoma

- 40 times less common than basal cell carcinoma
- predisposing factors
  - spontaneous
  - from areas of solar injury and actinic keratosis
  - immunodeficiency
- more aggressive
  - may metastasize
    - lymphatic transmission
    - blood-borne transmission
    - direct extension, often along nerves
- treatment
  - similar to those for basal cell carcinoma
  - Mohs micrographic resection
  - surgical excision with wide margins and frozen sections
  - recurrent squamous cell carcinoma
    - wide surgical resection
    - orbital exenteration
    - ± neck dissection
      - may require collaboration with a head and neck cancer surgeon
  - hedgehog pathway and epidermal growth factor receptor (EGFR) inhibitors
    - for patients who are not candidates for surgery

Ophthalmology Mind Maps/Arman Mashayekhi, MD