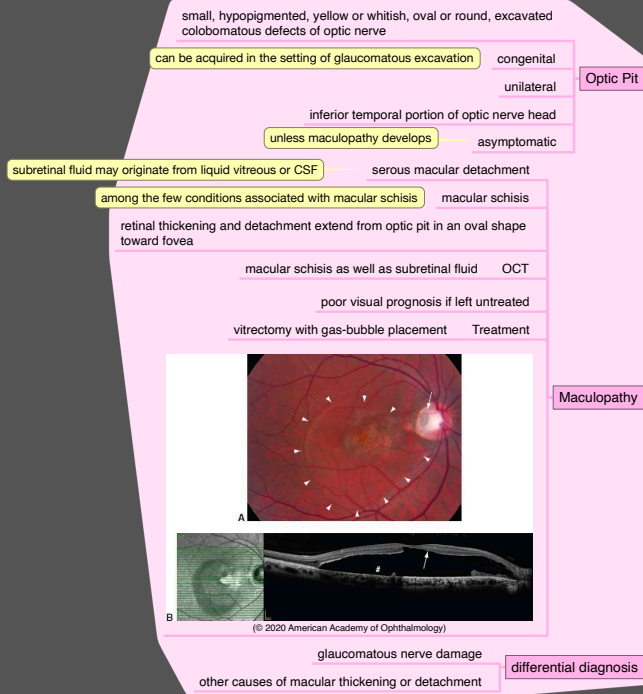
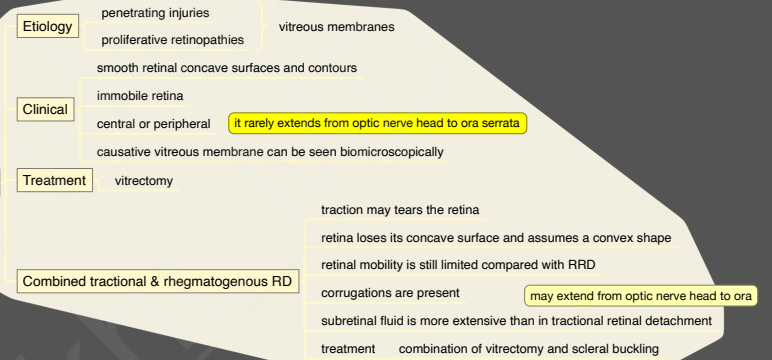


Retinal Detachment II

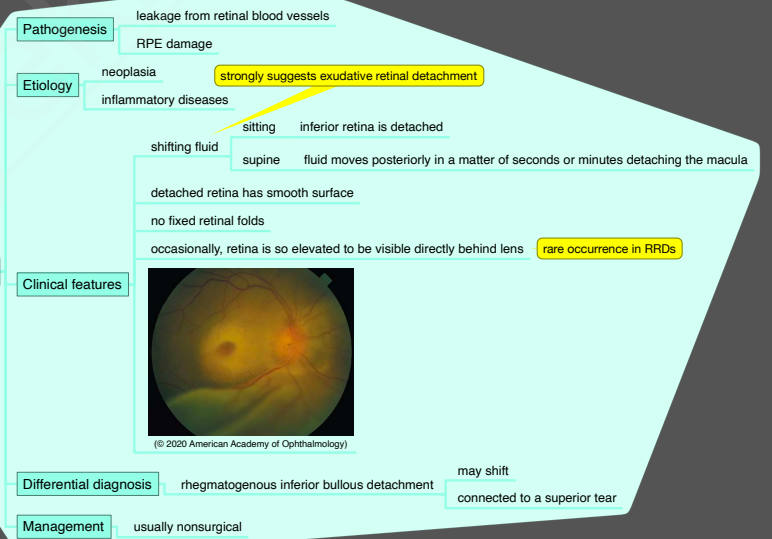
Optic Pit Maculopathy



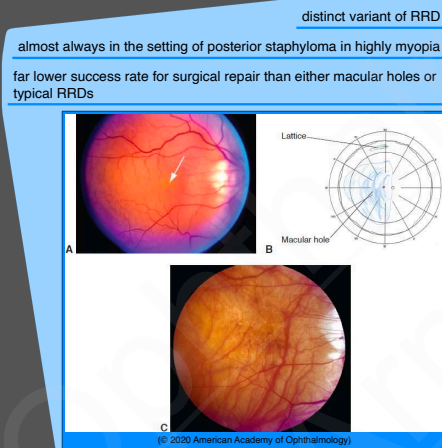
Tractional Retinal Detachment



Exudative Retinal Detachment



Macular Holes in High Myopia



peripheral cystoid degeneration

