8.12.5. Degenerative Changes in the Cornea (IV)

Scleral Degenerations

- decrease in scleral hydration
- decrease in scleral mucopolysaccharide
- calcium deposition
  - diffuse
  - (focal) senile plaques
    - anterior to the horizontal rectus muscle insertions
    - ovoid or rectangular zones of grayish translucency
    - surrounded by relatively acellular collagen
    - midportion of involved sclera contains a focal calcified plaque
    - rarely extrude
    - may be visualized on CT scan

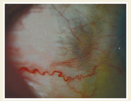

Figure 12-16 (© 2020 American Academy of Ophthalmology)

- increase in scleral rigidity
- subconjunctival fat deposition
  - gives the sclera a yellowish appearance

Endothelial Degenerations

Iridocorneal endothelial syndrome

- endothelial cells take on the ultrastructural characteristics of epithelial cells
  - progressive endothelialization
    - anterior chamber angle
      - peripheral anterior synechiae
      - glaucoma
    - iris surface
      - iris changes
- herpesvirus DNA has been identified in cornea & aqueous humor
- middle-aged females
- almost always unilateral
- clinical variations
  - Chandler variant
    - disease is confined to the inner corneal surface
    - corneal edema from subnormal endothelial pump function
  - essential iris atrophy variant
    - abnormal endothelium spreads onto the surface of the iris
      - iris atrophy
      - corectopia
      - polycoria

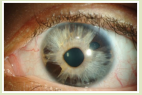

Figure 12-15 (© 2020 American Academy of Ophthalmology)

  - Cogan-Reese variant (iris nevus syndrome)
    - membrane grows on the anterior iris surface
      - pinches off islands of the normal iris stroma
      - tan pedunculated nodules or diffuse pigmented lesions on the anterior iris surface
      - nodular/nevus-like appearance
- treatment
  - penetrating keratoplasty
  - endothelial keratoplasty
  - control of intraocular pressure

Peripheral cornea guttae (Hassall-Henle bodies)

- normal aging change
- small, wartlike excrescences of Descemet membrane
  - protrude toward the anterior chamber
- slit lamp exam
  - small, dark dimples within the endothelial mosaic
- best seen by specular reflection
- increase steadily in number with age
  - rarely < age 20
- in the central cornea, they are pathologic
  - "cornea guttae"
  - associated with progressive stromal and eventually epithelial edema
    - Fuchs endothelial dystrophy

Melanin pigmentation

- Krukenberg spindle
  - pigment dispersion syndrome
  - pigment on the corneal endothelium
    - vertically oriented

Ophthalmology Mind Maps
Arman Mashayekhi, MD