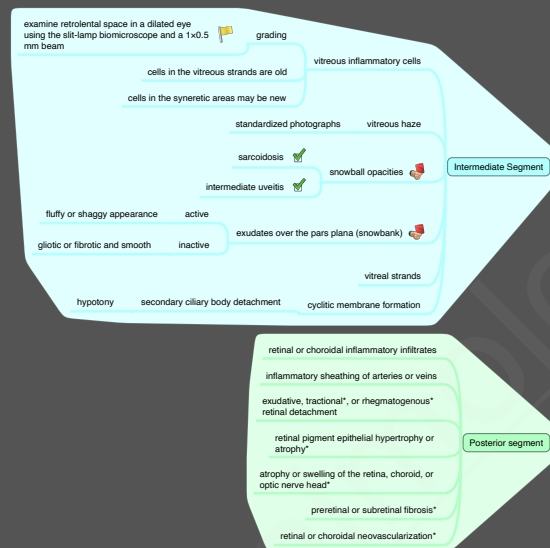

9.5.2. Clinical Approach to Uveitis (II): Signs

Anterior segment

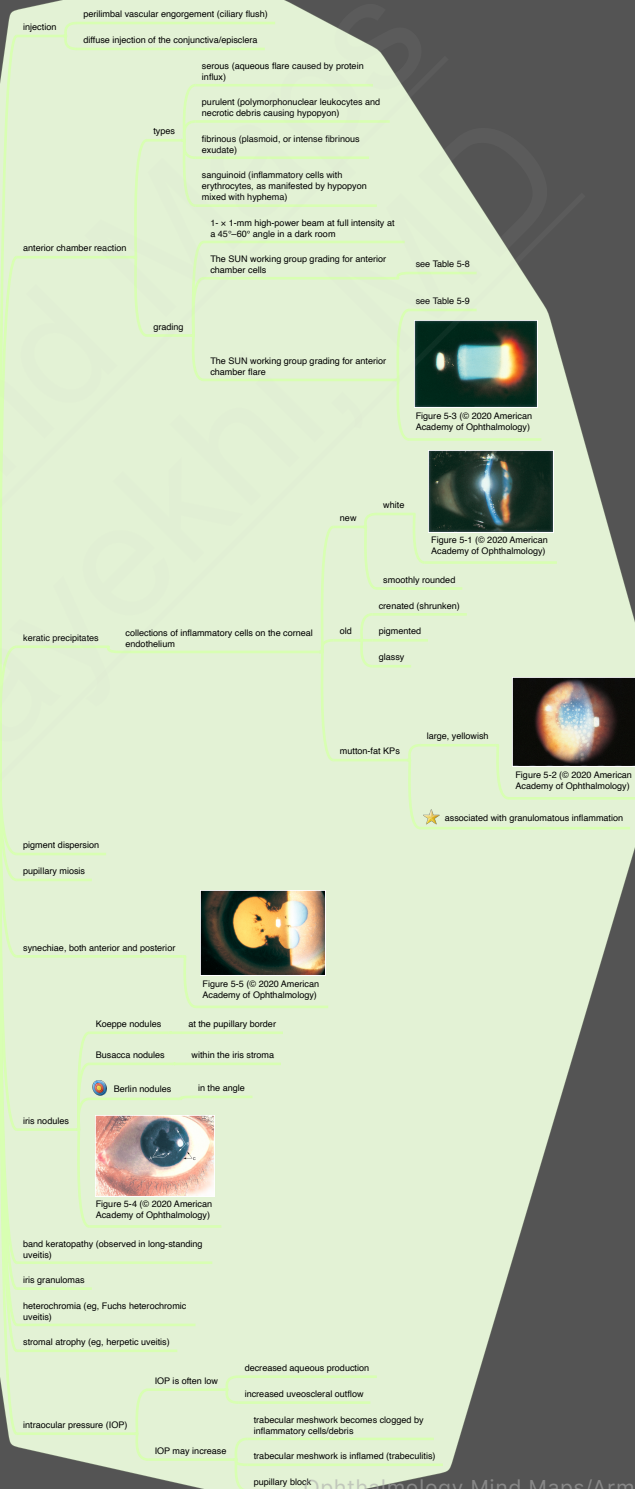


Figure 5-3 (© 2020 American Academy of Ophthalmology)

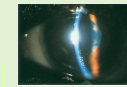


Figure 5-1 (© 2020 American Academy of Ophthalmology)

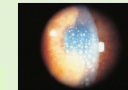


Figure 5-2 (© 2020 American Academy of Ophthalmology)



Figure 5-5 (© 2020 American Academy of Ophthalmology)

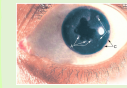


Figure 5-4 (© 2020 American Academy of Ophthalmology)